Keyhole Surgery for Primary and Metastatic Brain Tumors: Less is More

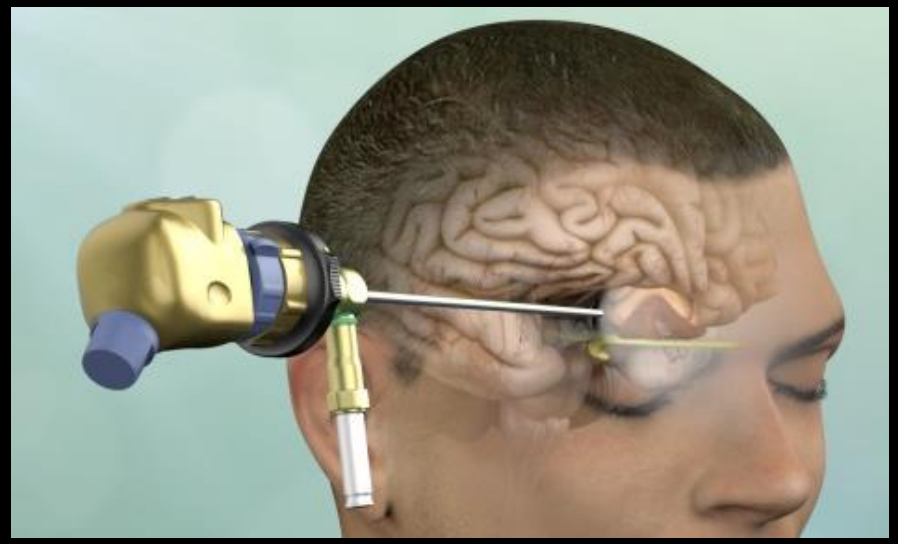



Daniel F. Kelly, MD

Colleagues: Achal Achrol, Garni Barkhoudarian, Dave Hoon, John Jalas, Santosh Kesari, Walavan Sivakumar, Yuki Takasumi, Robert Wollman

Sheri Palejwala, Felipe Sfeir, Xiang Fabio Huang

PACIFIC NEUROSCIENCE INSTITUTE℠

Saint John's Health Center
PROVIDENCE Health & Services

JOHN WAYNE CANCER INSTITUTE
at Providence Saint John's Health Center

Disclosures

- Mizuho, Inc. - royalties

Common Brain & Skull Base Tumors

Standardized Incidence Rates

(new cases/100,000 persons/year)

Tumor Type	SIR	In USA/yr
• Meningioma	7.7	26,000
• ***Glioma***	***7.1***	***20,000***
• Pituitary adenoma	3.2	11,000
• Schwannoma	1.9	6000
• **Total Primary Brain Tumors**		**71,000**
• ***Brain Metastases***		***250,000***


Neuro-Oncology

Neuro-Oncology 17:iv1–iv62, 2015.
doi:10.1093/neuonc/nov189

CBTRUS Statistical Report: Primary Brain and Central Nervous System Tumors Diagnosed in the United States in 2008-2012

Quinn T. Ostrom M.A., M.P.H.[1,2*], Haley Gittleman M.S.[1,2*], Jordonna Fulop R.N.[1], Max Liu[3], Rachel Blanda[4], Courtney Kromer B.A.[5], Yingli Wolinsky Ph.D., M.B.A.[1,2], Carol Kruchko B.A.[2], and Jill S. Barnholtz-Sloan Ph.D.[1,2]

Brain Metastases: Treatment Progress?

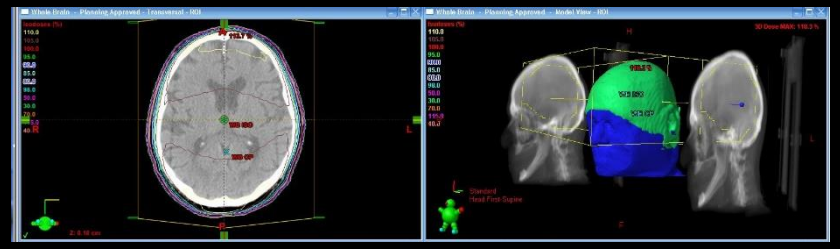

- Hope & Prayer
- Surgery & WBRT of solitary metastasis (Patchell 1990)

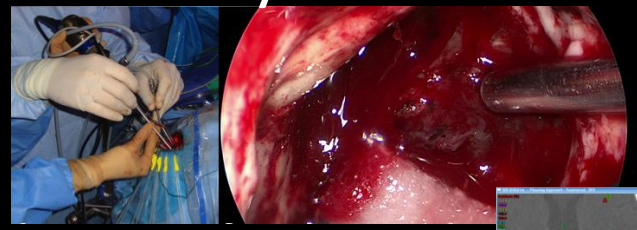

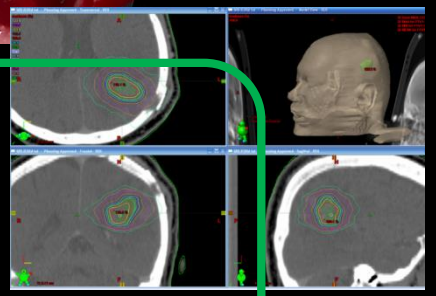

- Minimally Invasive Surgery
- Radiosurgery
- Targeted Therapies & Immunotherapy

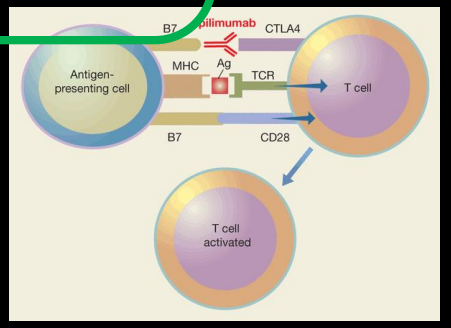

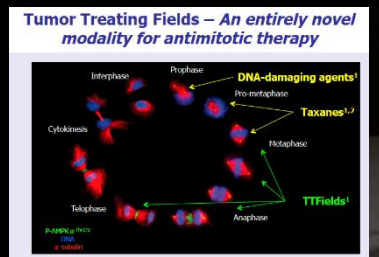

Brain Metastases Surgery

- Prompt elimination of mass effect and neurologic deficits
- Confirm diagnosis & tumor profiling
- Rapid ability to taper steroids
- Optimize patient for radiosurgery, targeted therapies

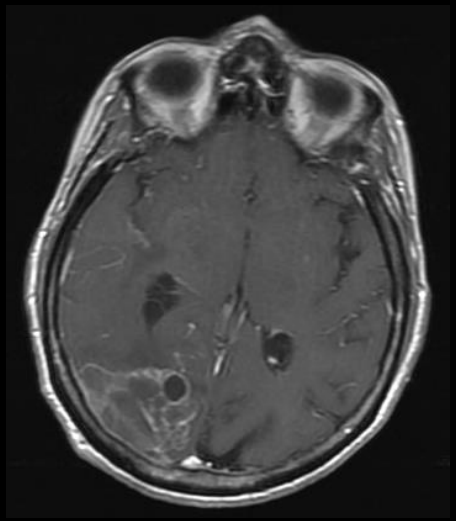

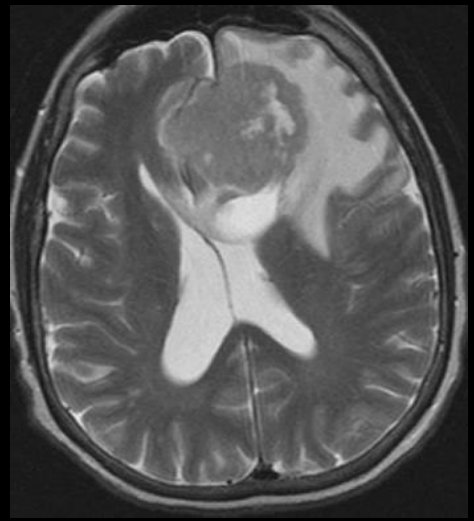

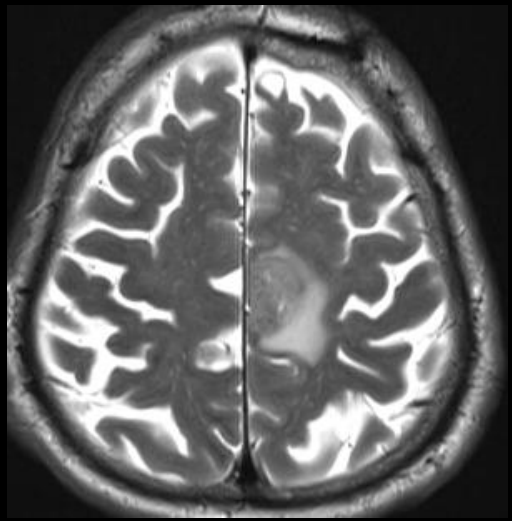

Stereotactic radiosurgery boost to the resection bed for oligometastatic brain disease: challenging the tradition of adjuvant whole-brain radiotherapy

Brian J. Karlovits, D.O.,[1] Matthew R. Quigley, M.D.,[2,3]
Stephen M. Karlovits, M.D.,[1,3] Lindsay Miller,[1] Mark Johnson, M.S.,[1]
Olivier Gayou, Ph.D.,[1] and Russell Fuhrer, M.D.[1,3]

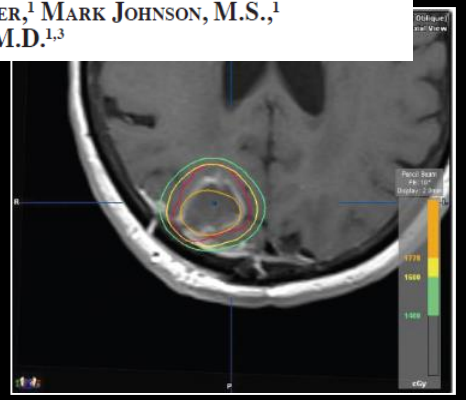

Brain Metastases: Surgical Indications

- Expected survival > 3 months & good perform. status (KPS>70)
- One or 2 large accessible sxic or inflammatory metastasis (>2 cm) including in or near eloquent cortex
- Large symptomatic lesion in setting of multiple small metastases
- Failed SRS or radio-necrosis with persistent mass effect, edema, steroid-dependence

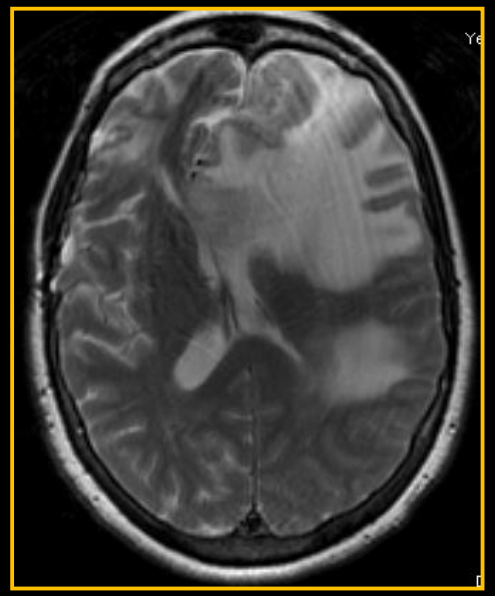

Glioma Surgery: Balance of aggressive resection & neurological deterioration



JNS
ATLAS
CLINICAL ARTICLE
J Neurosurg 127:111–122, 2017

Aggressive resection at the infiltrative margins of glioblastoma facilitated by intraoperative fluorescein guidance

*Justin A. Neira, MD,[1] Timothy H. Ung, MD,[1] Jennifer S. Sims, PhD,[1] Hani R. Malone, MD,[1] Daniel S. Chow, MD,[2] Jorge L. Samanamud,[1] George J. Zanazzi, MD, PhD,[4] Xiaotao Guo, PhD,[3] Stephen G. Bowden, BM,[1] Binsheng Zhao, DSc,[3] Sameer A. Sheth, MD, PhD,[1] Guy M. McKhann II, MD,[1] Michael B. Sisti, MD,[1] Peter Canoll, MD, PhD,[4] Randy S. D'Amico, MD,[1] and Jeffrey N. Bruce, MD[1]

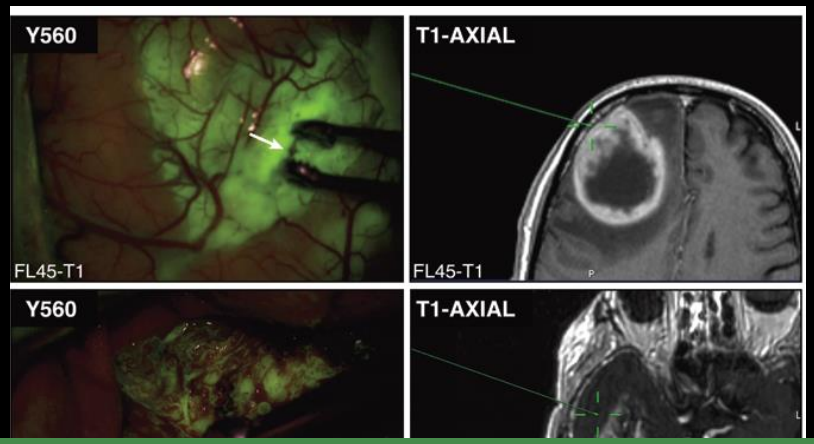

JNS
CLINICAL ARTICLE
J Neurosurg 127:123–131, 2017

The effects of new or worsened postoperative neurological deficits on survival of patients with glioblastoma

Maryam Rahman, MD, MS,[1] Joseph Abbatematteo, PharmD,[1] Edward K. De Leo, BS,[1] Paul S. Kubilis, MS,[1] Sasha Vaziri, MD,[1] Frank Bova, PhD,[1] Elias Sayour, MD, PhD,[1] Duane Mitchell, MD, PhD,[1] and Alfredo Quinones-Hinojosa, MD[2]

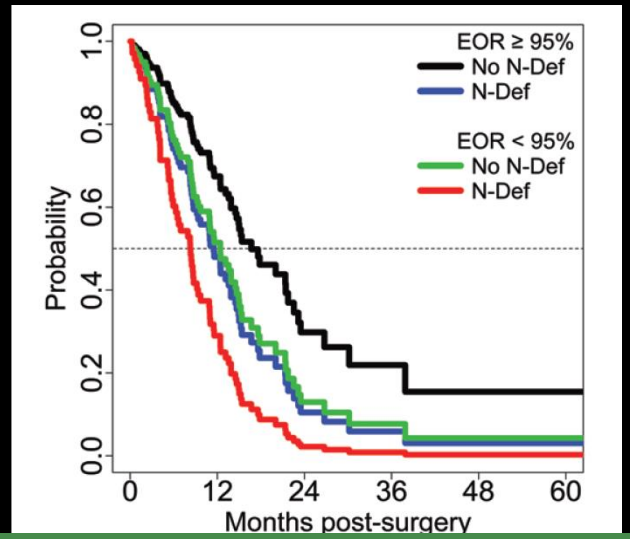

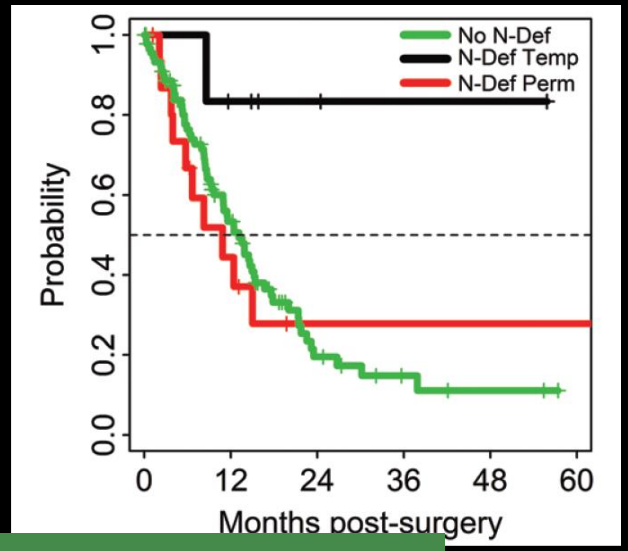

Technical adjuncts help us remove more tumor…
EOR impacts survival but so do new/worsened neurological deficits

Less
is more

Principals of Malignant Brain Tumor Surgery

- This is only the beginning of treatment…
- Aim for maximal safe resection to restore function & QOL
- Obtain sufficient tissue for biomarkers & targeted therapies
- Avoid new neurological deficits
- Surgical approach that promotes early mobilization & short hospital stay
- Optimize patient for adjuvant therapies

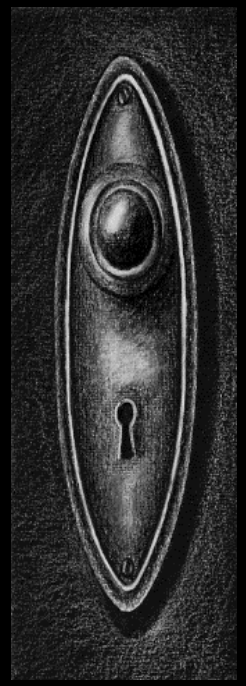

- How do we accomplish this?

Keyhole Surgery

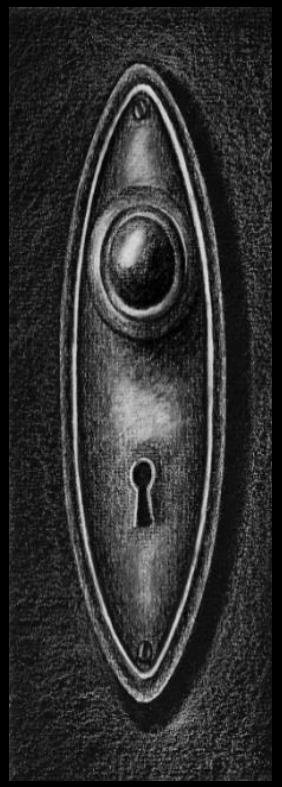

Removing tumors via smaller, more precise openings to minimize brain, scalp and muscle manipulation

- Less bone removal
- Less soft tissue disruption
- Less brain retraction
- Less collateral damage

Less
is more

“Sneak in & sneak out”

Approach Evolution

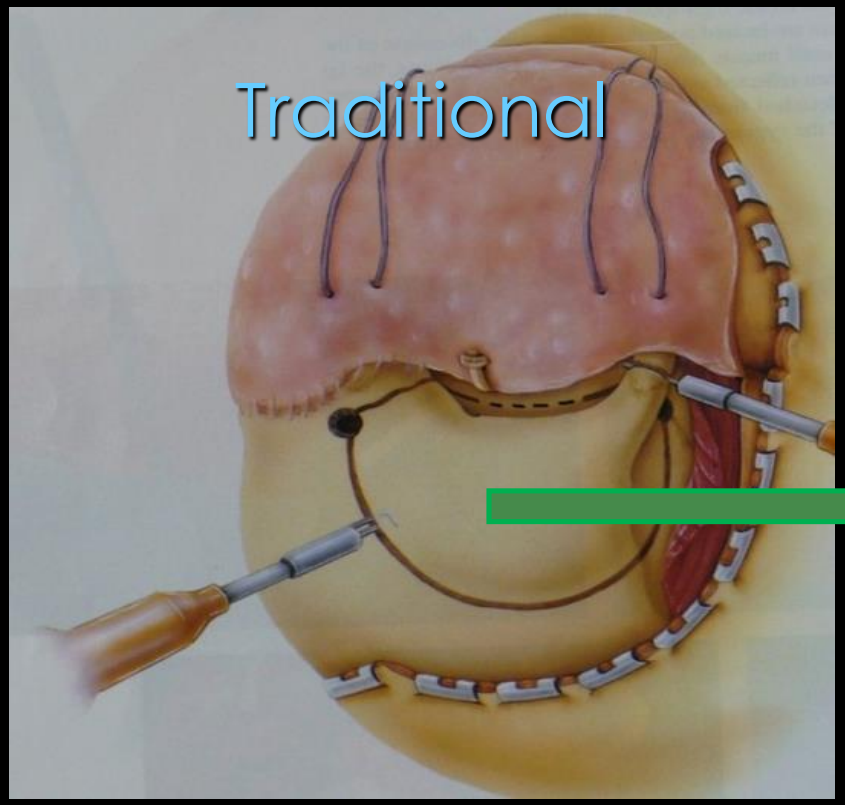

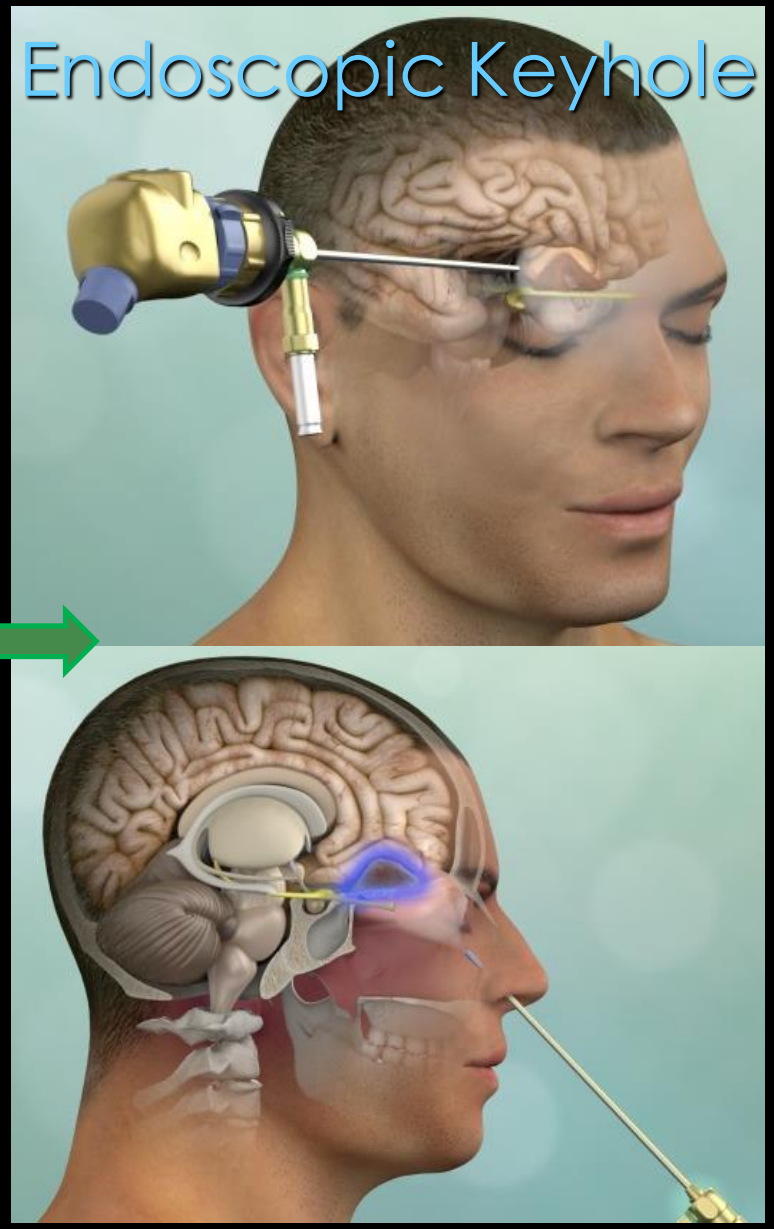

Endoscopic visualization & Keyhole Surgery

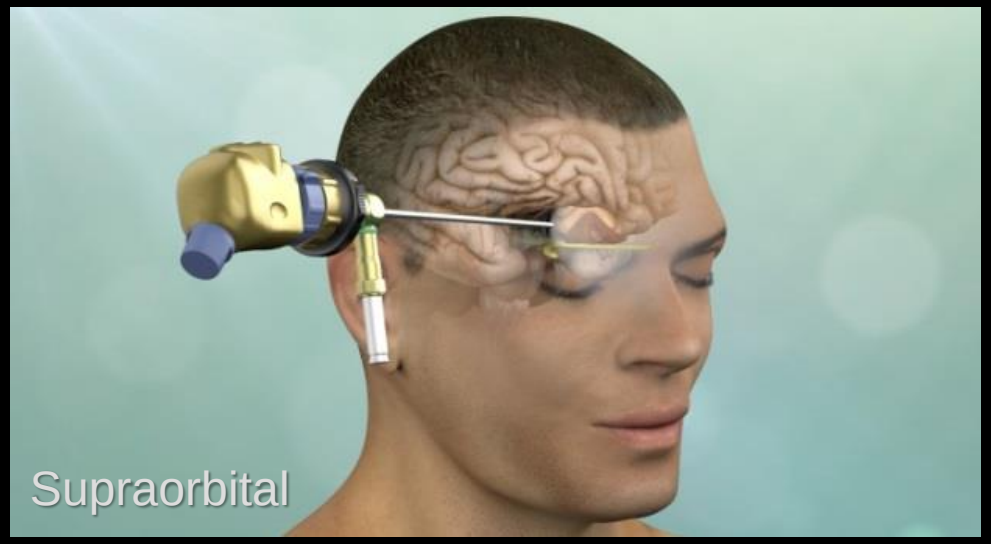

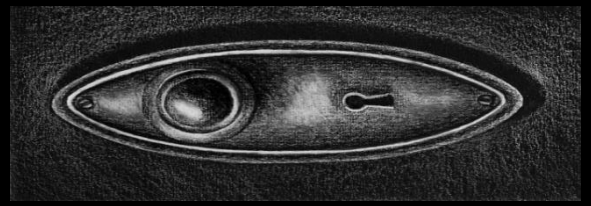

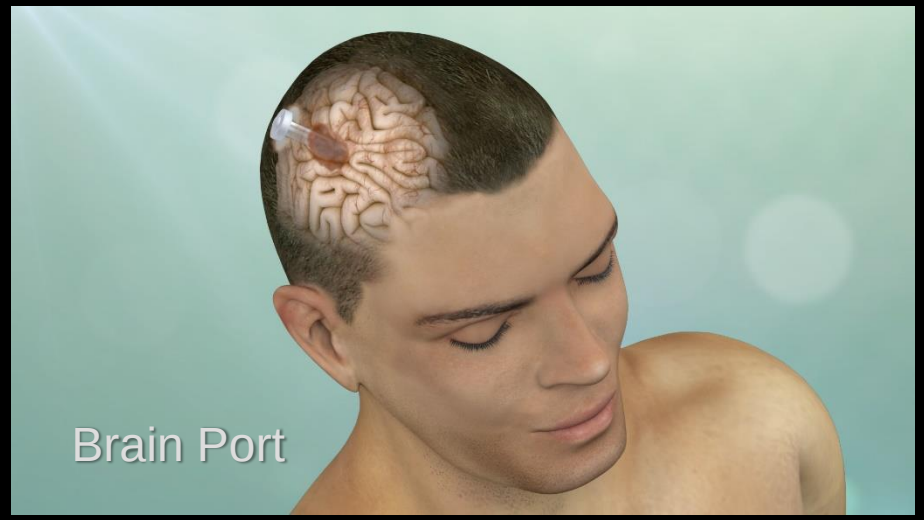

Instrumentation & Technology for Safe Surgery

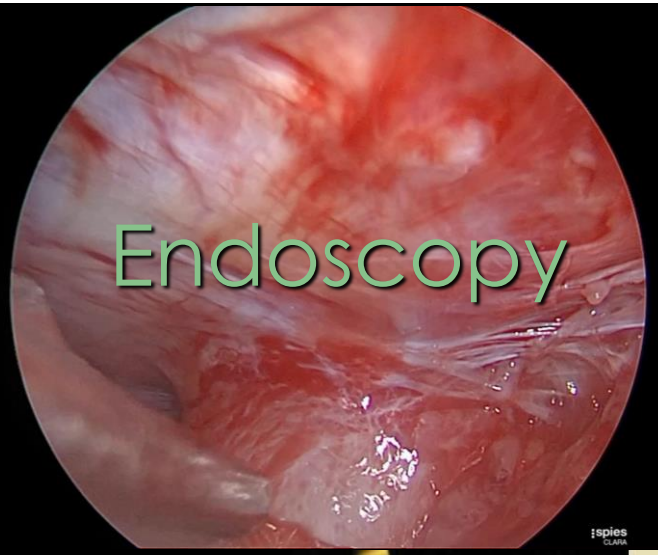

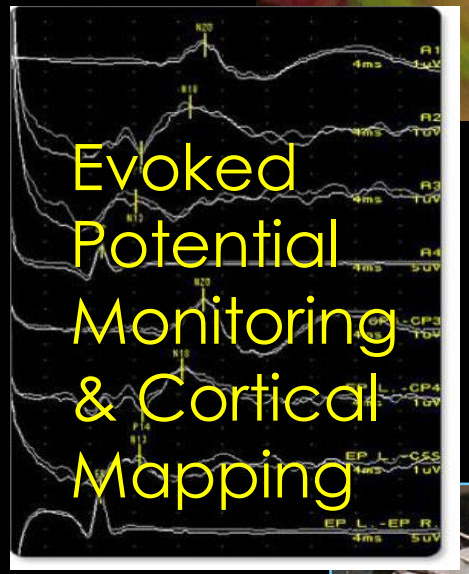

Navigation

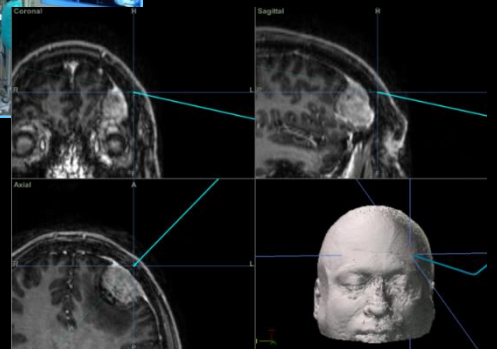

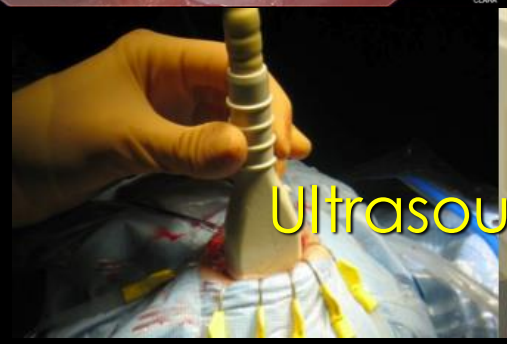

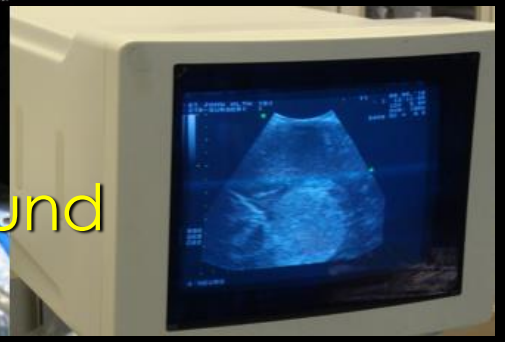



Use of Endoscope for Tumor Removal

- Endoscopic look & learn
- Endoscope-assisted removal
- Fully endoscopic removal

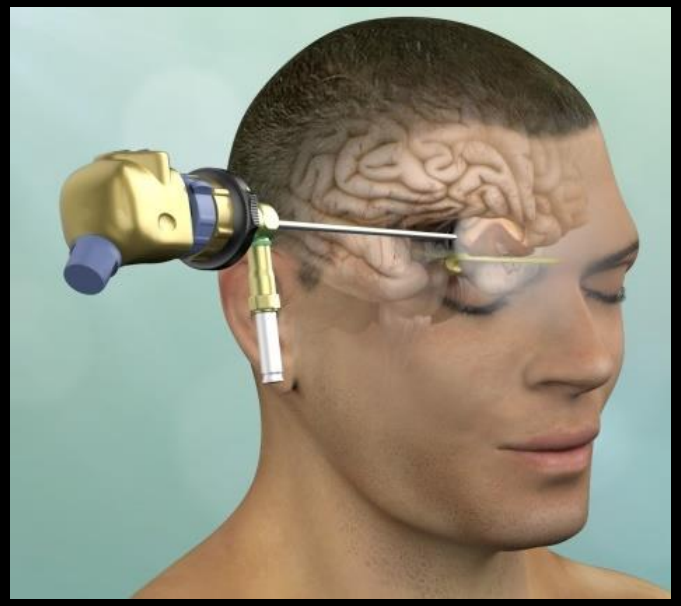

2-Handed Microsurgery

Most craniotomy case are endoscope-assisted

Room set-up for Endoscopic Craniotomy

- Patient positioning, scopes, monitors…

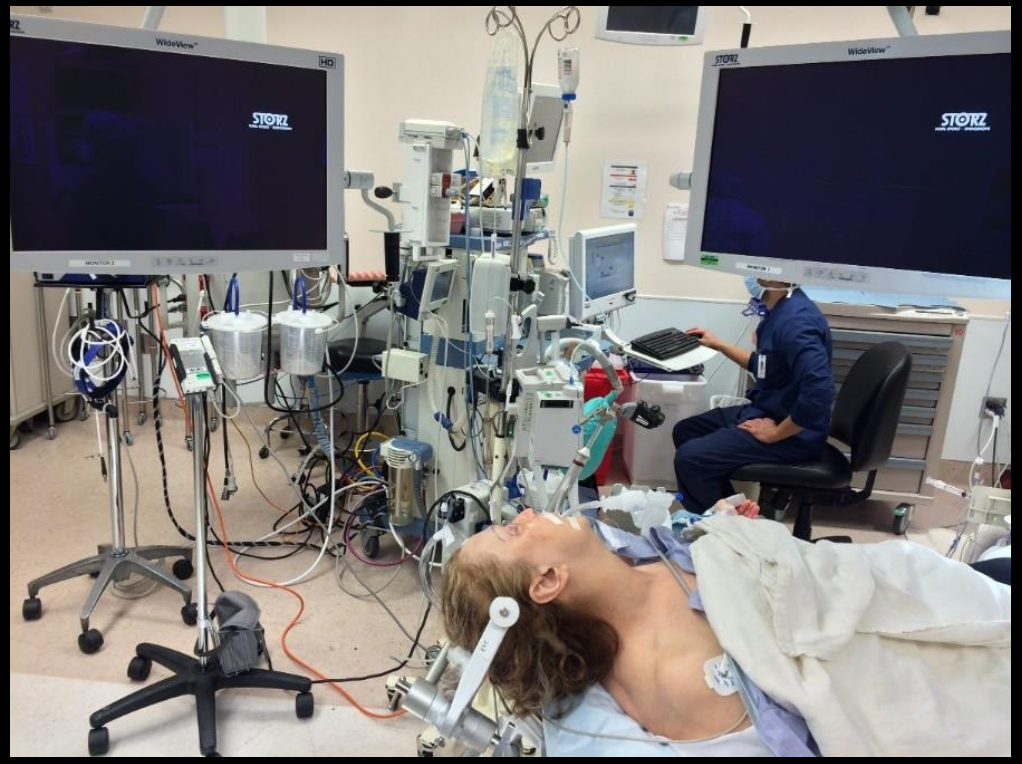

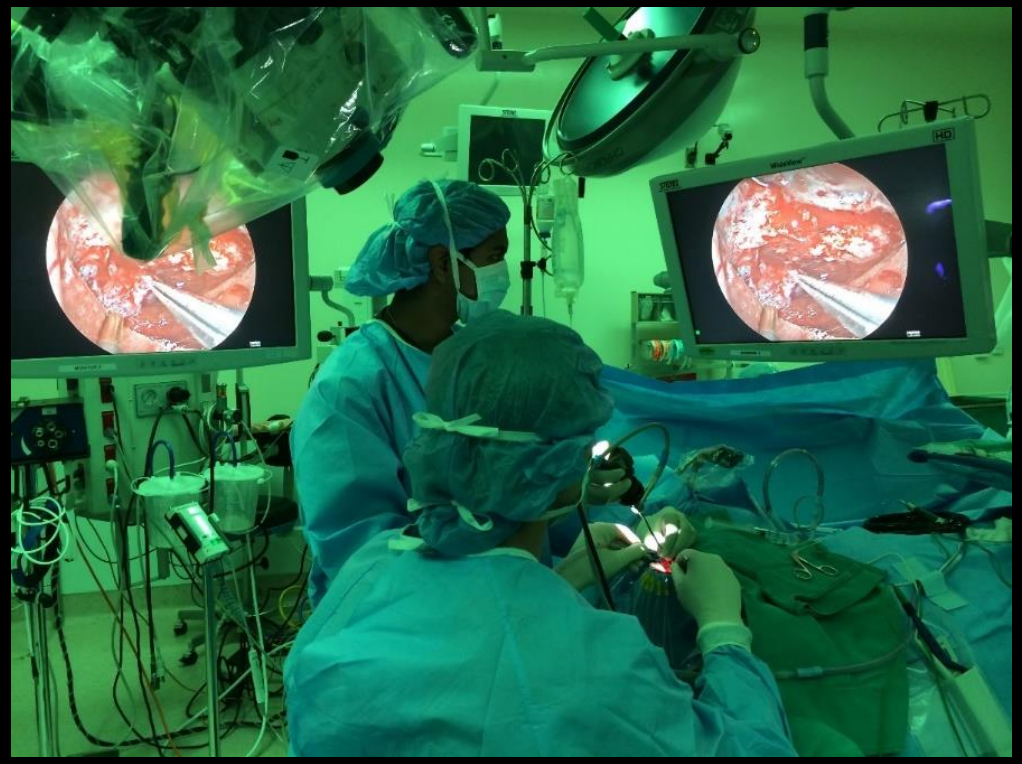

Supraorbital Eyebrow Craniotomy

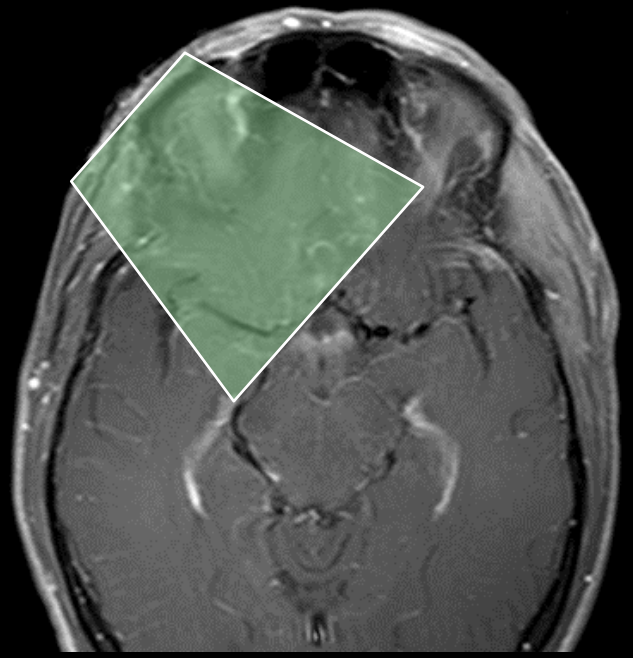

- "Sweet-spot" of fronto-temporal craniotomy
- Entry point on floor of frontal fossa
- Exposure of frontal fossae, parasellar & peri-sylvian regions
- View and access expanded with endoscopy

Chiasmal /Lamina Terminalis Tumor

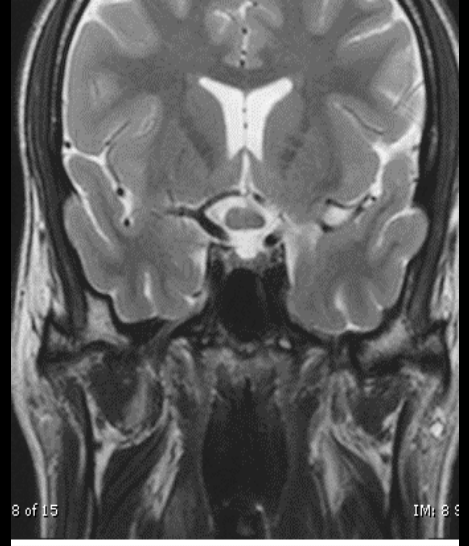

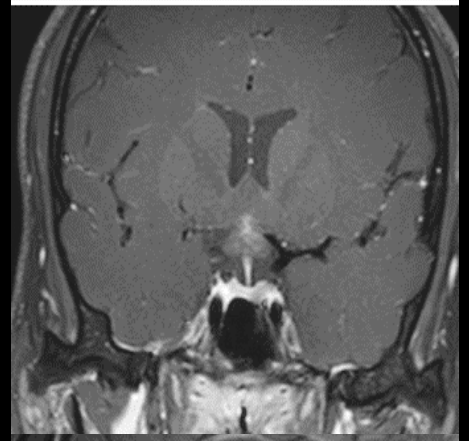

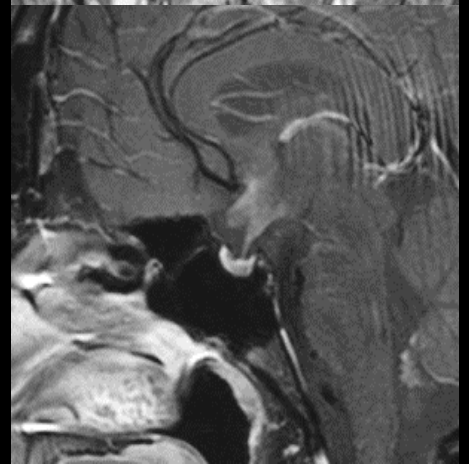

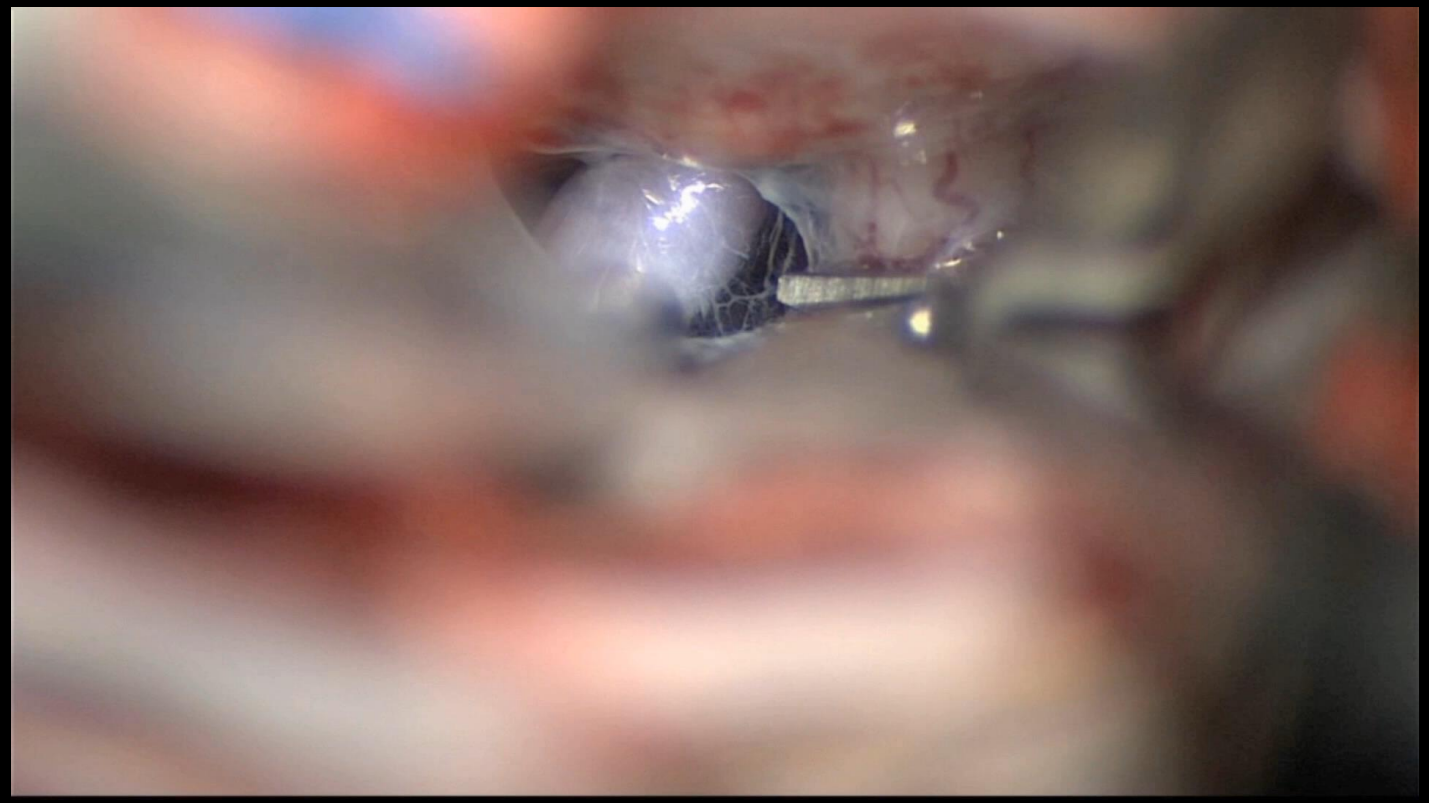

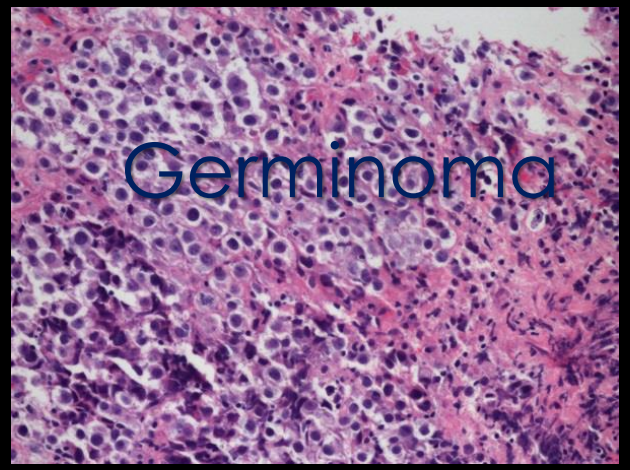

Anterior Cranial Fossa Meningiomas Accessible via Eyebrow

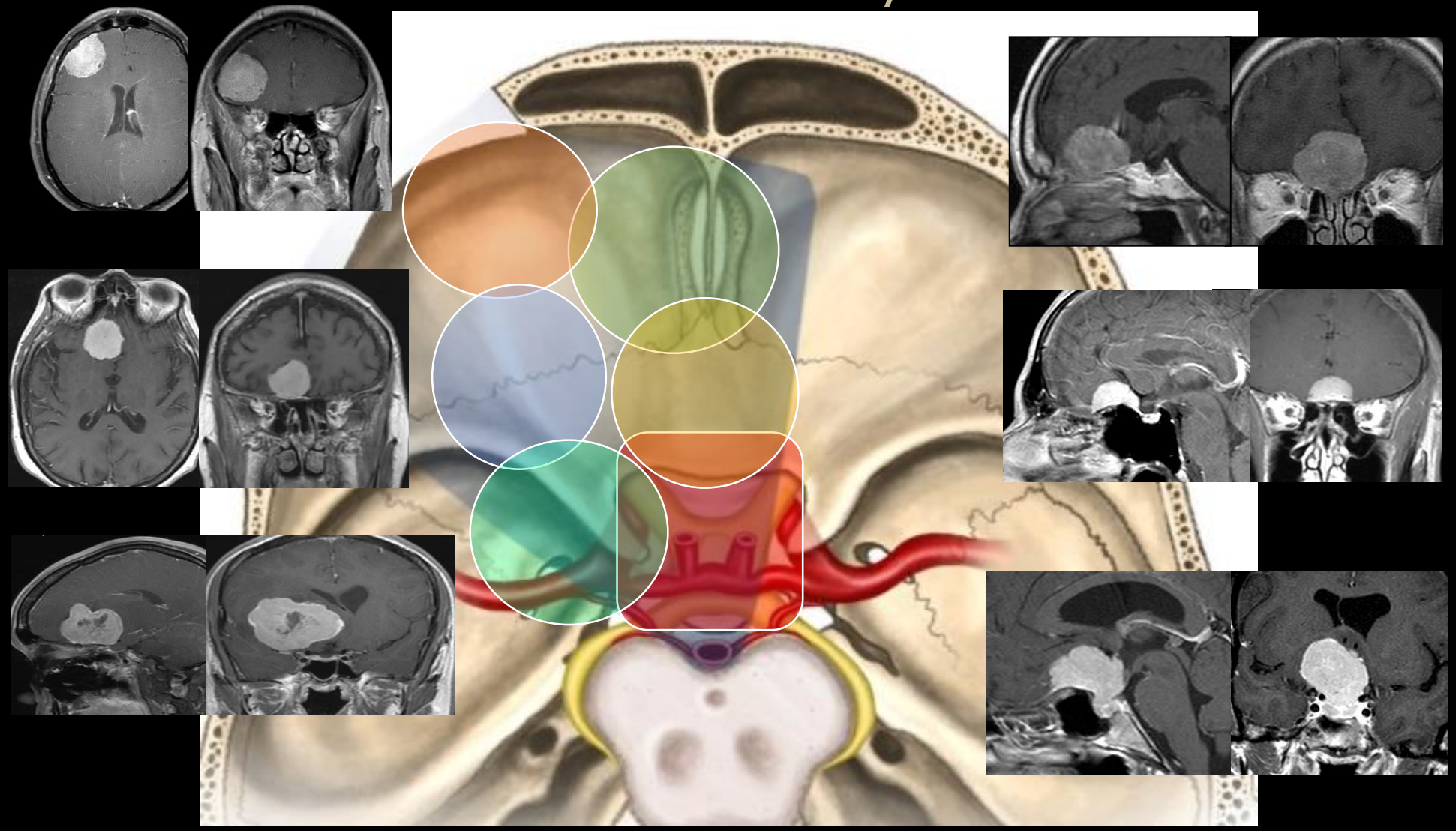

Convexity Meningioma

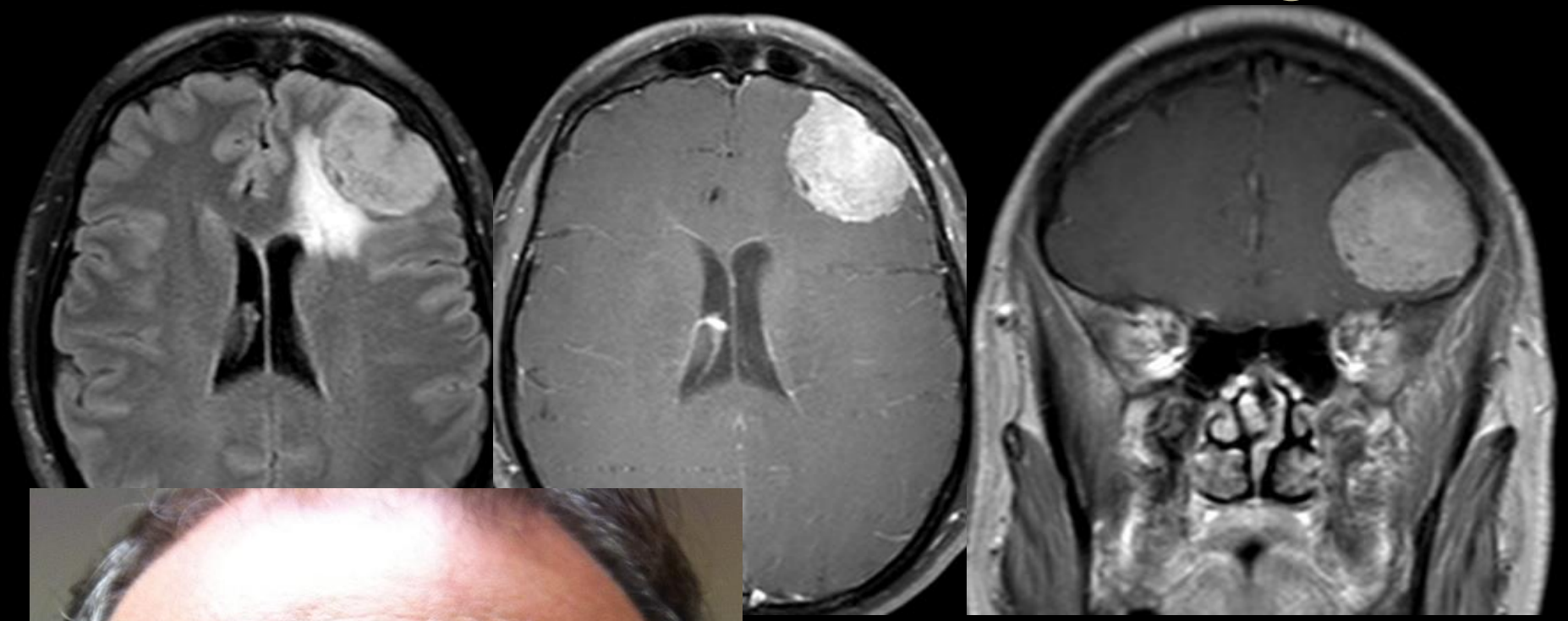

1 Year Post-op

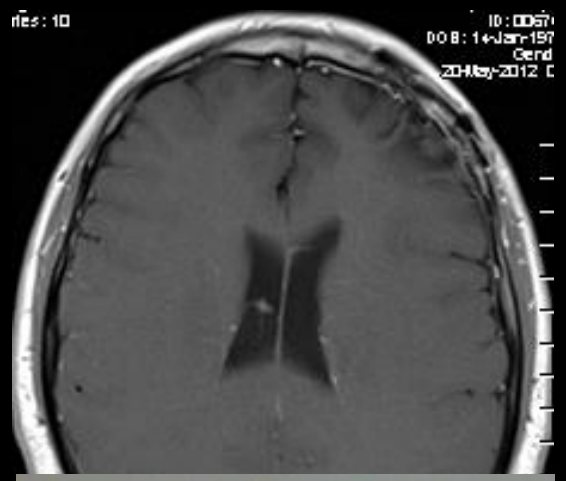

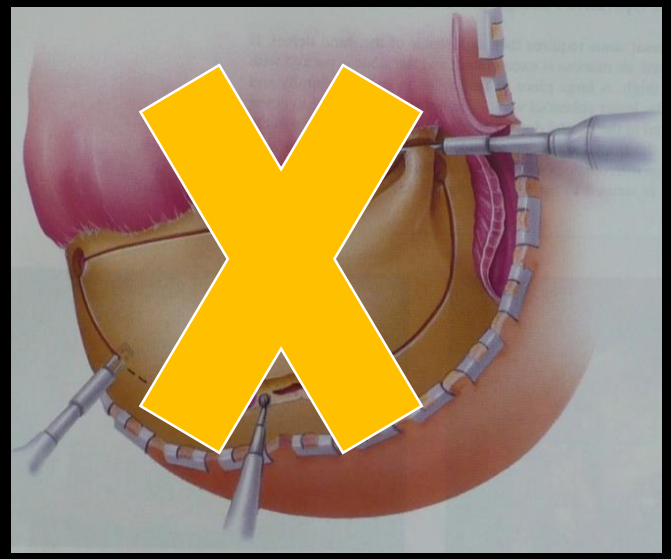

Intra-axial Brain Tumors Accessible via SO Route

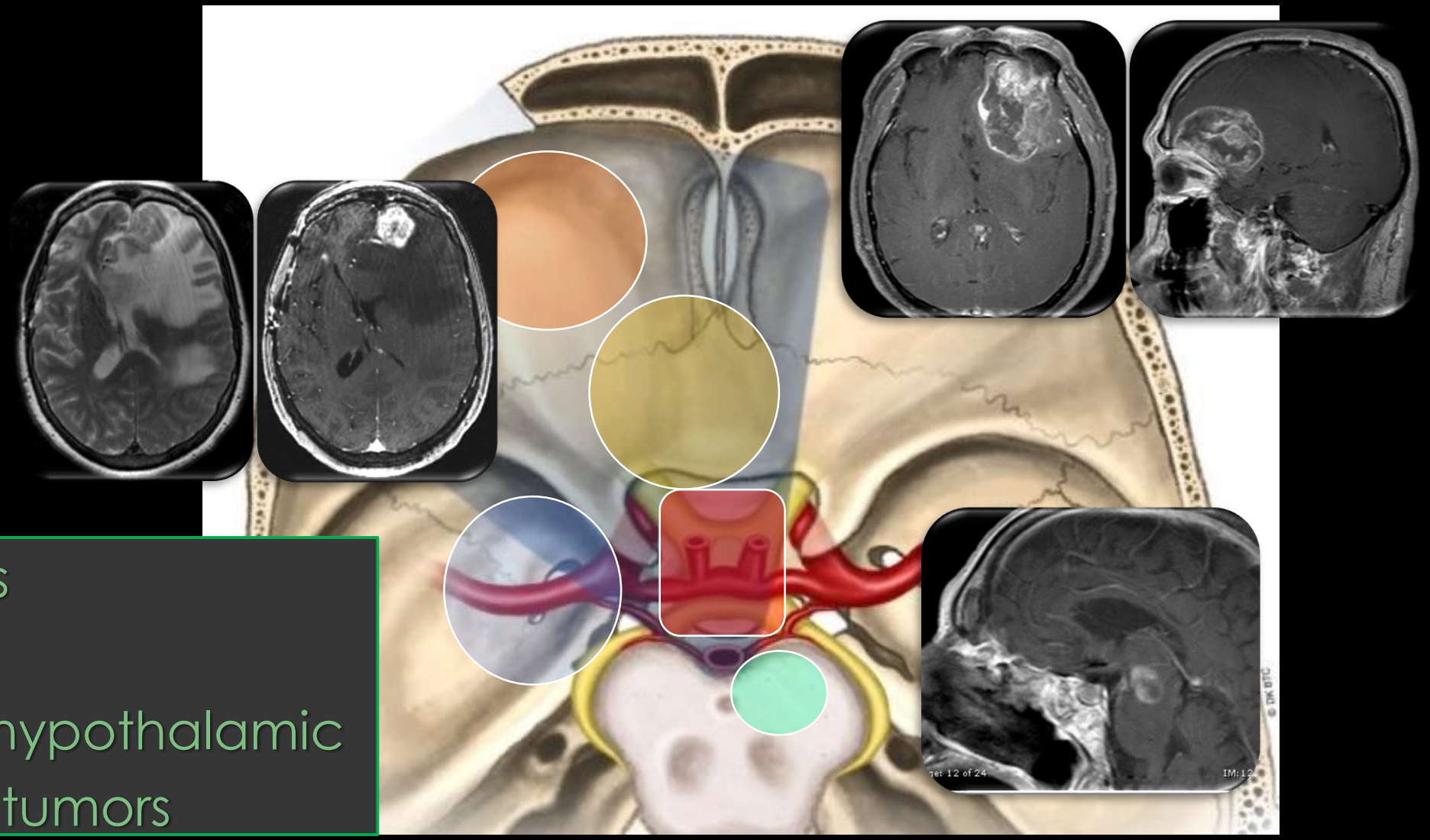

Metastases
Gliomas
Chiasmal/hypothalamic
Brain stem tumors

Eyebrow Removal of Brain Metastasis

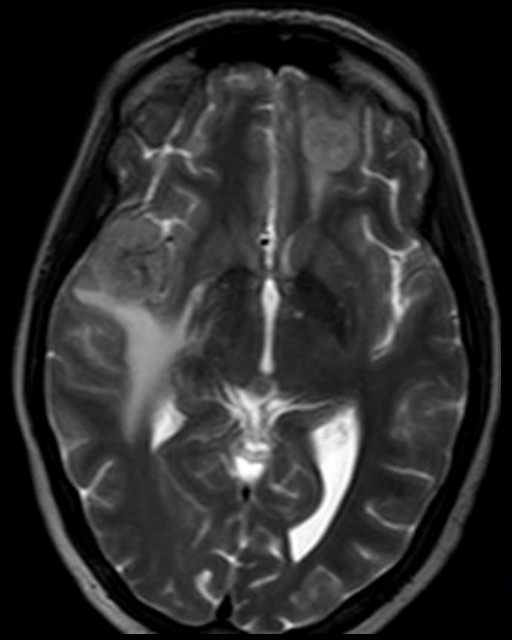

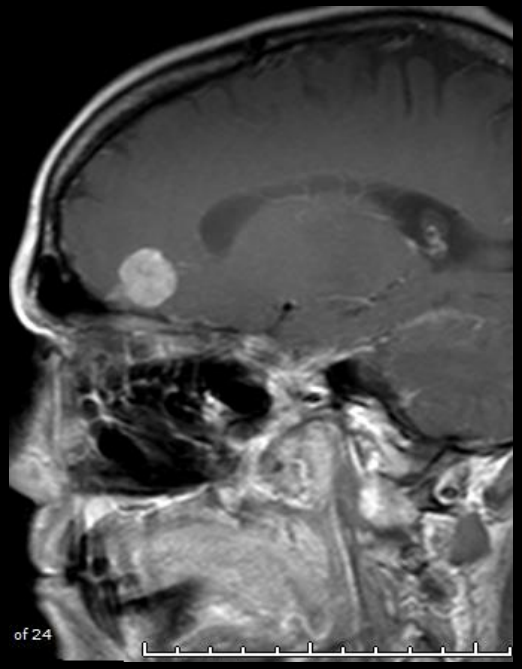

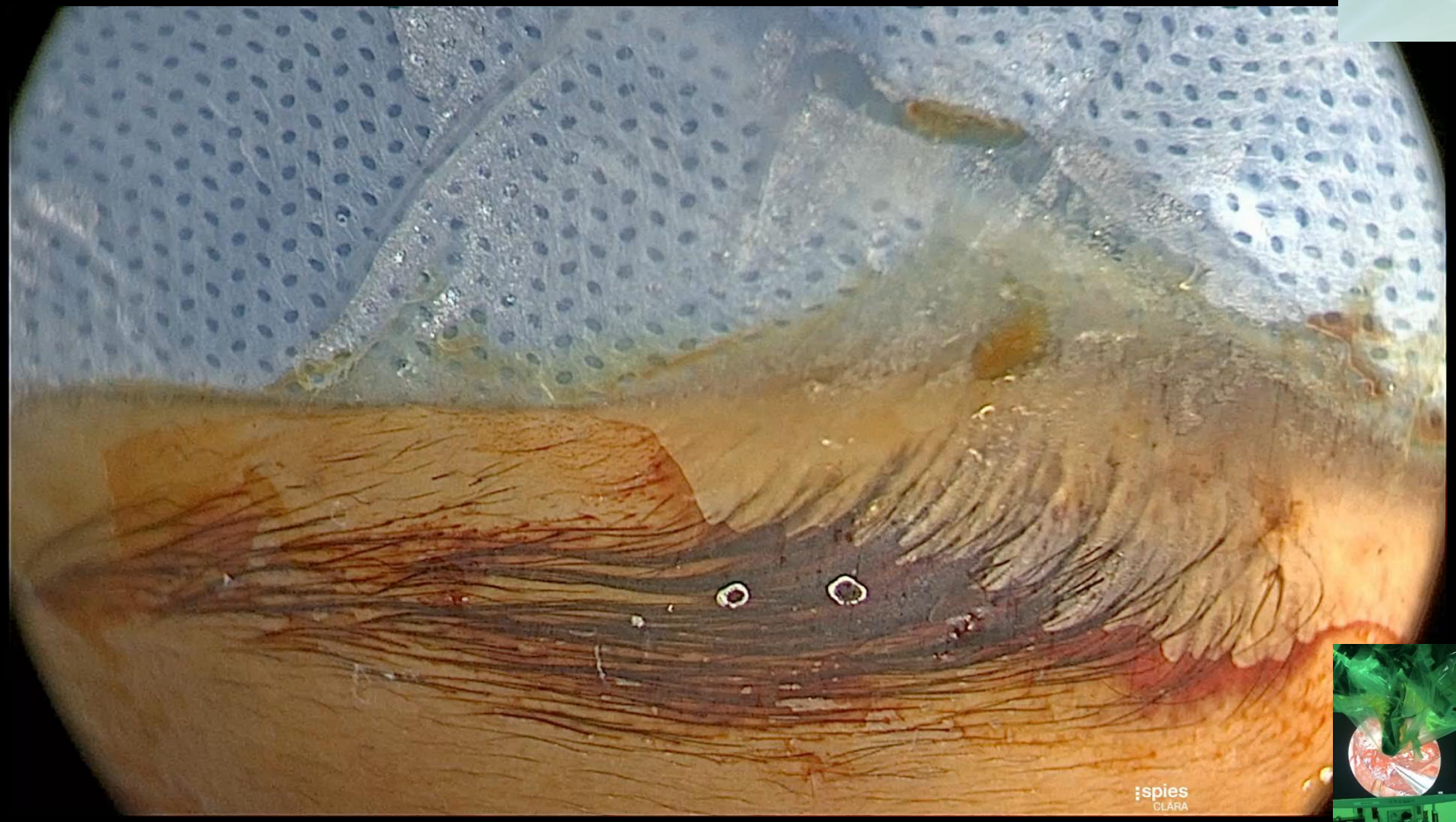

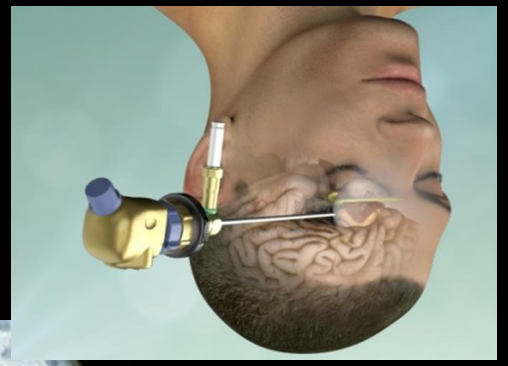

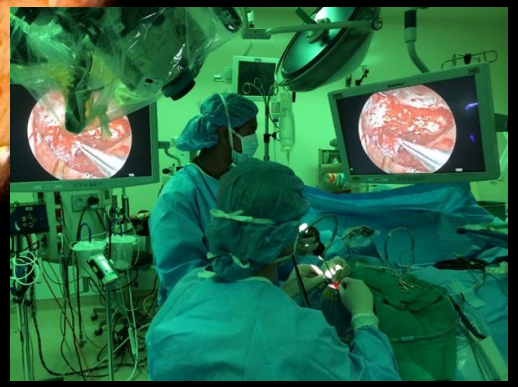

62 yr old woman with NSC lung carcinoma & cognitive decline after SRS

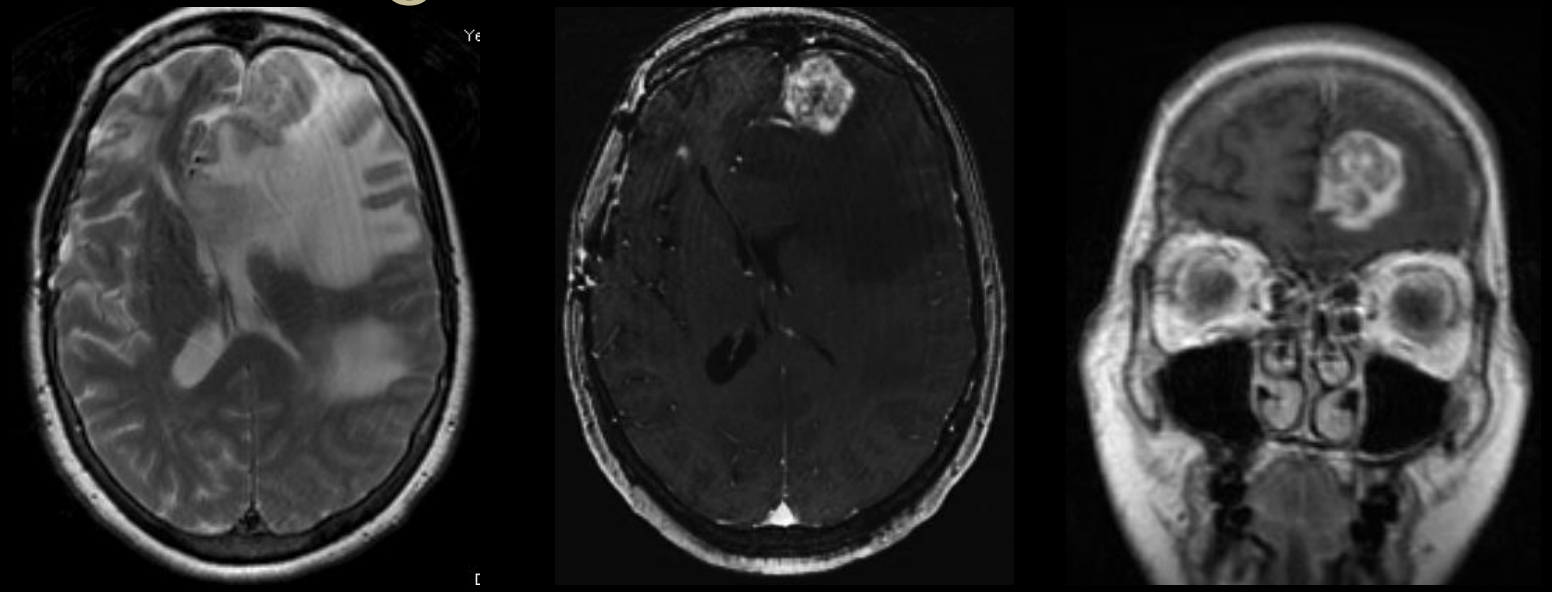

3 months after left supraorbital craniotomy

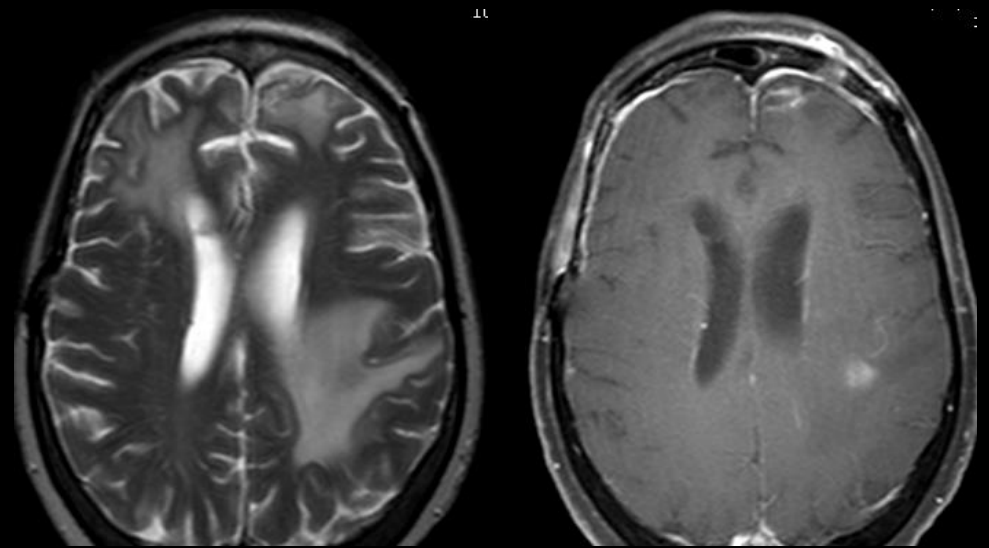

Pathology: radiation necrosis with minimal viable carcinoma

Recurrent Glioblastoma – left eyebrow craniotomy

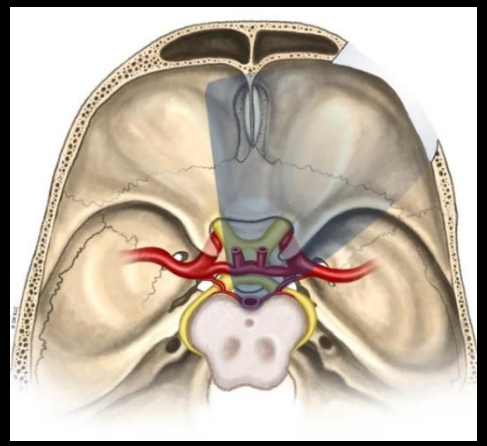

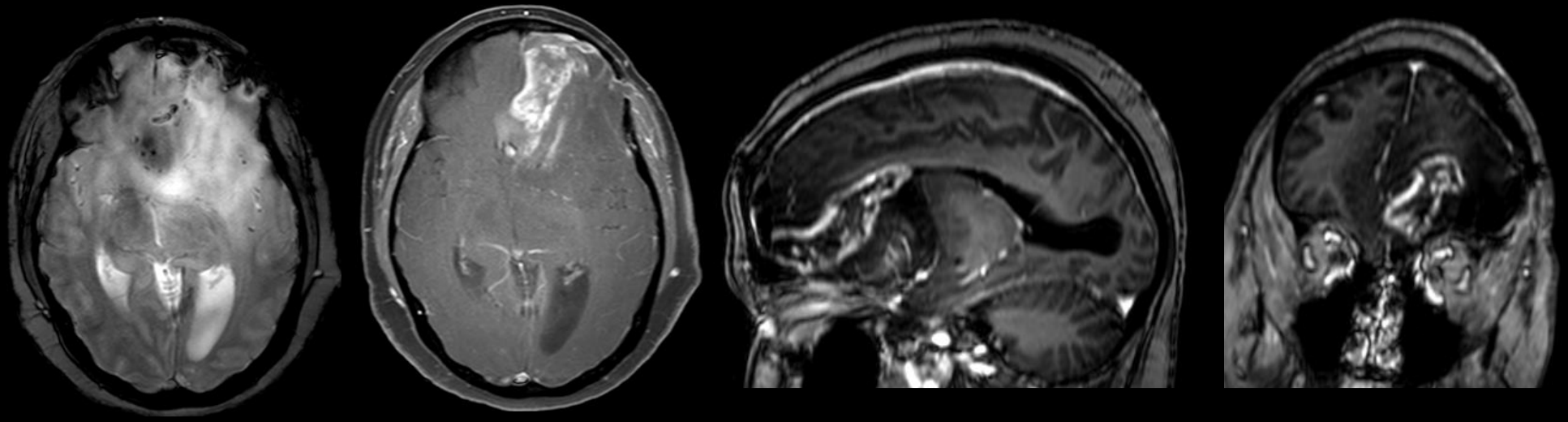

Recurrent Glioblastoma – left eyebrow craniotomy

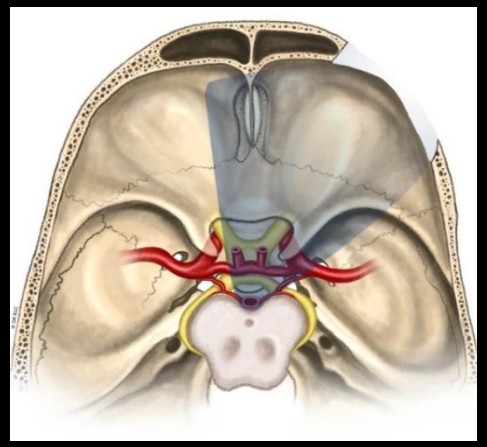

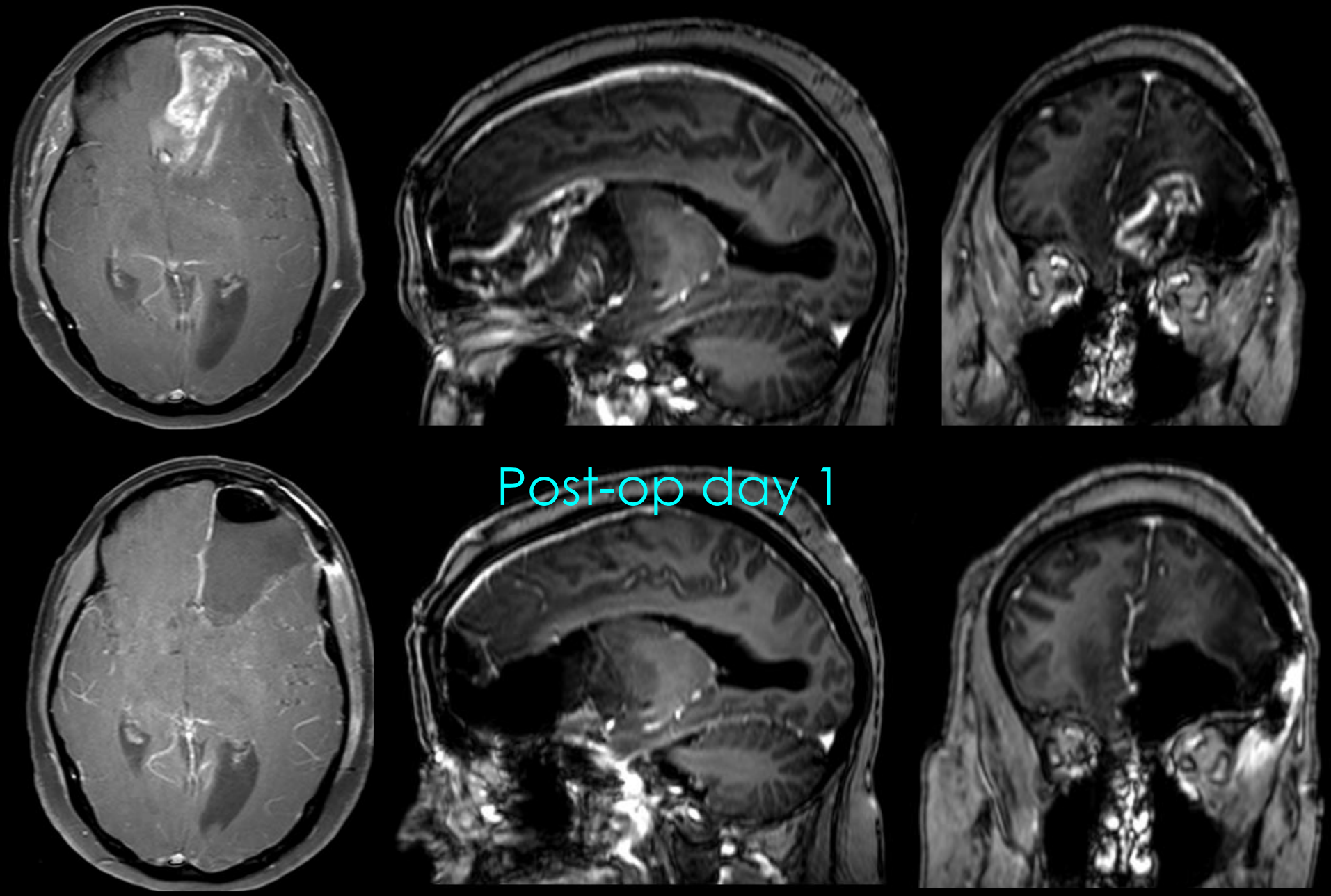

Midbrain Tumor: 82 yr old woman with gait instability, memory decline, diplopia

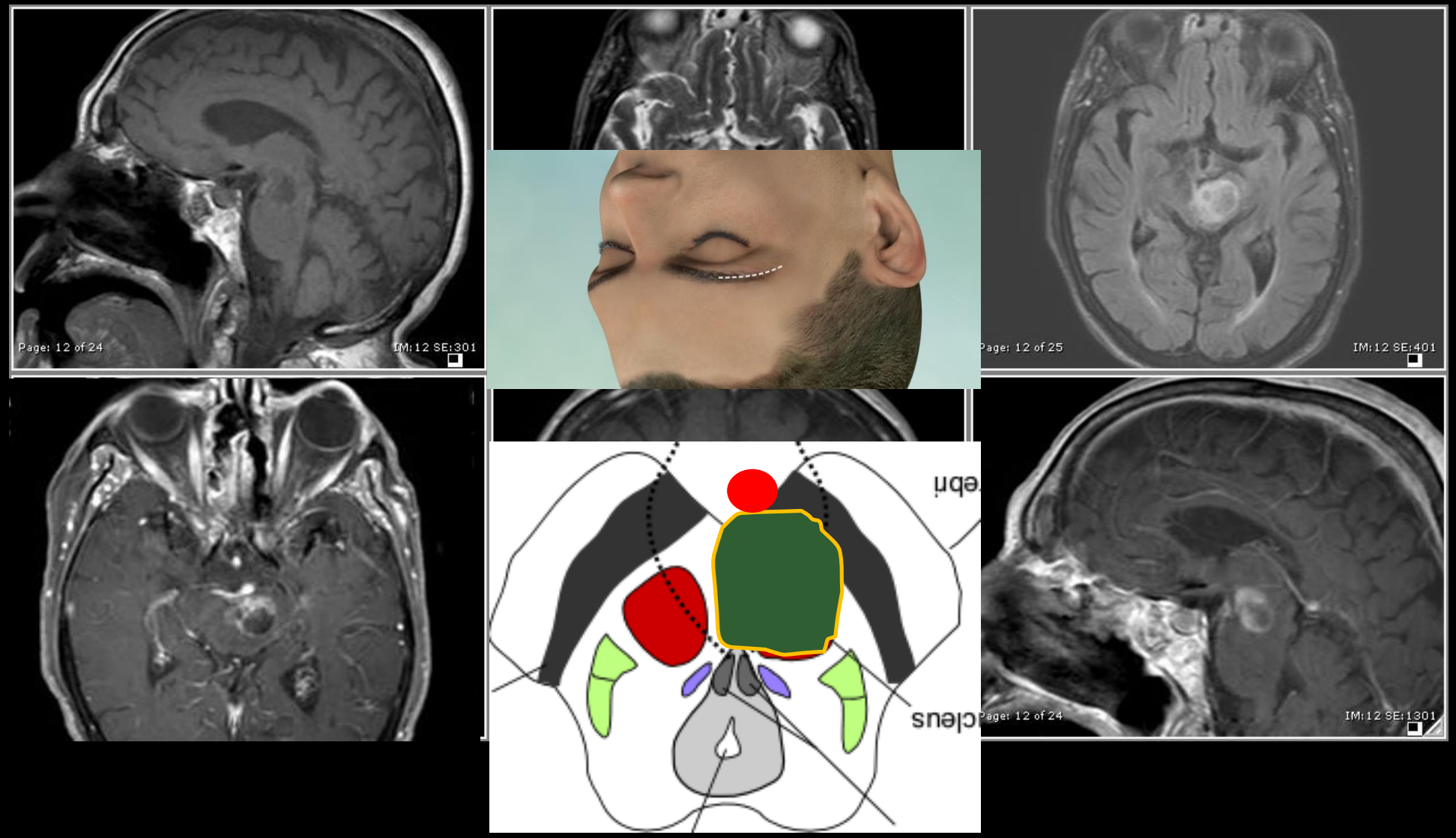

Left midbrain lesion approached via right eyebrow craniotomy

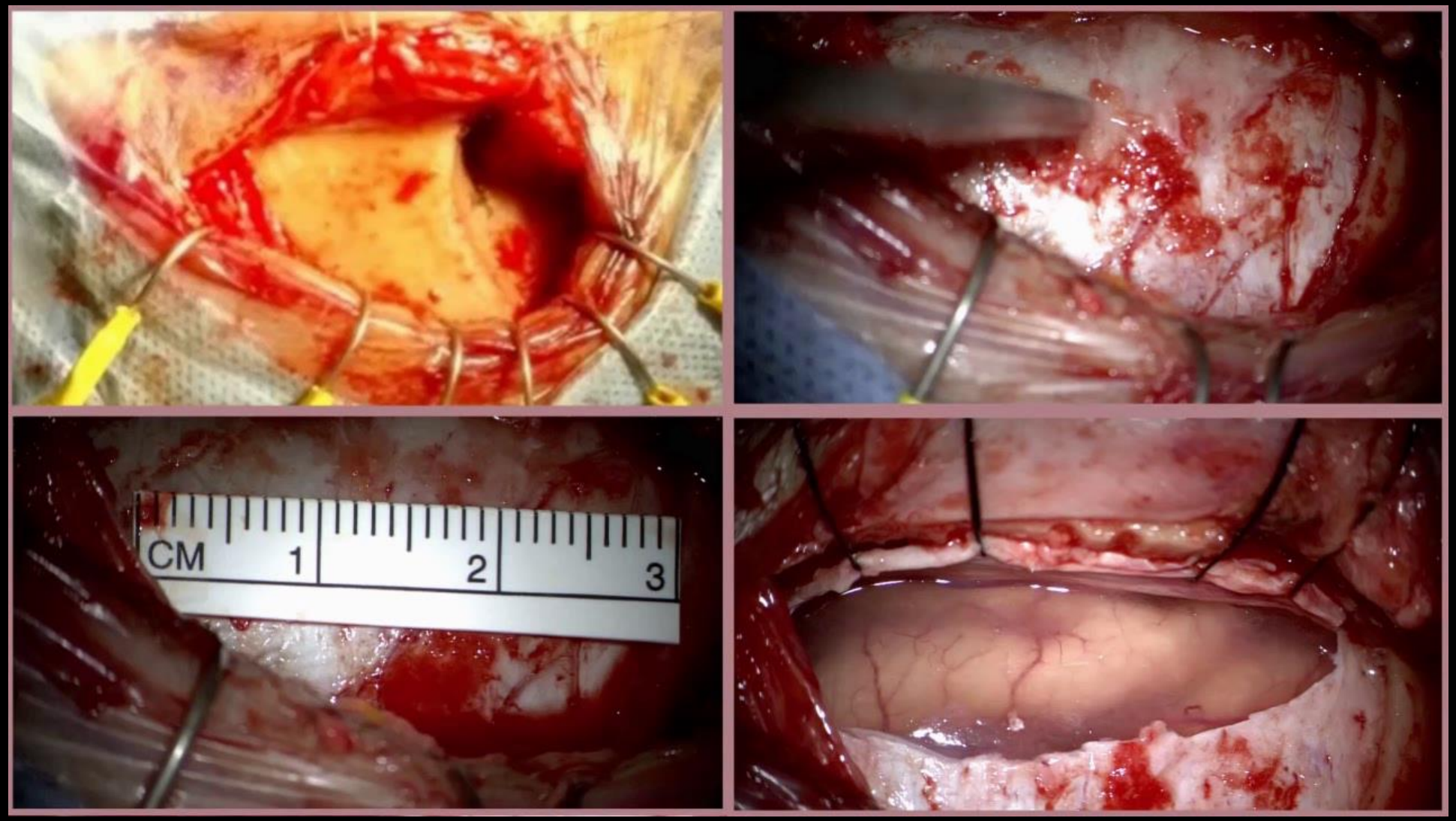

Supra-orbital Craniotomy:

Excellent exposure & brain-friendly

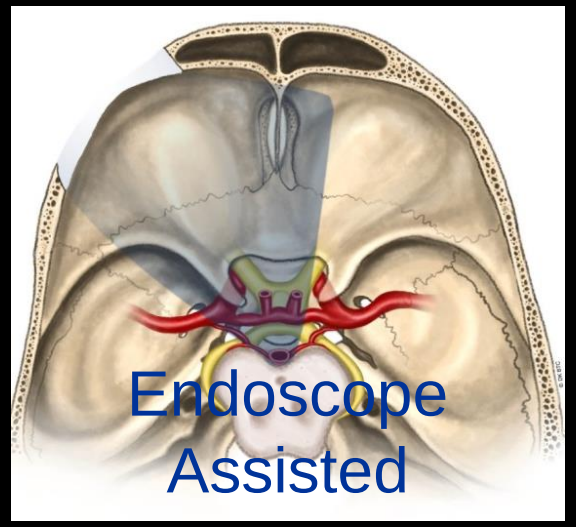

Cosmesis more than acceptable

Gravity-Assisted Endoscopic Trans-Dural Approaches

To Access Lesions Within or Surrounded by Eloquent Cortex

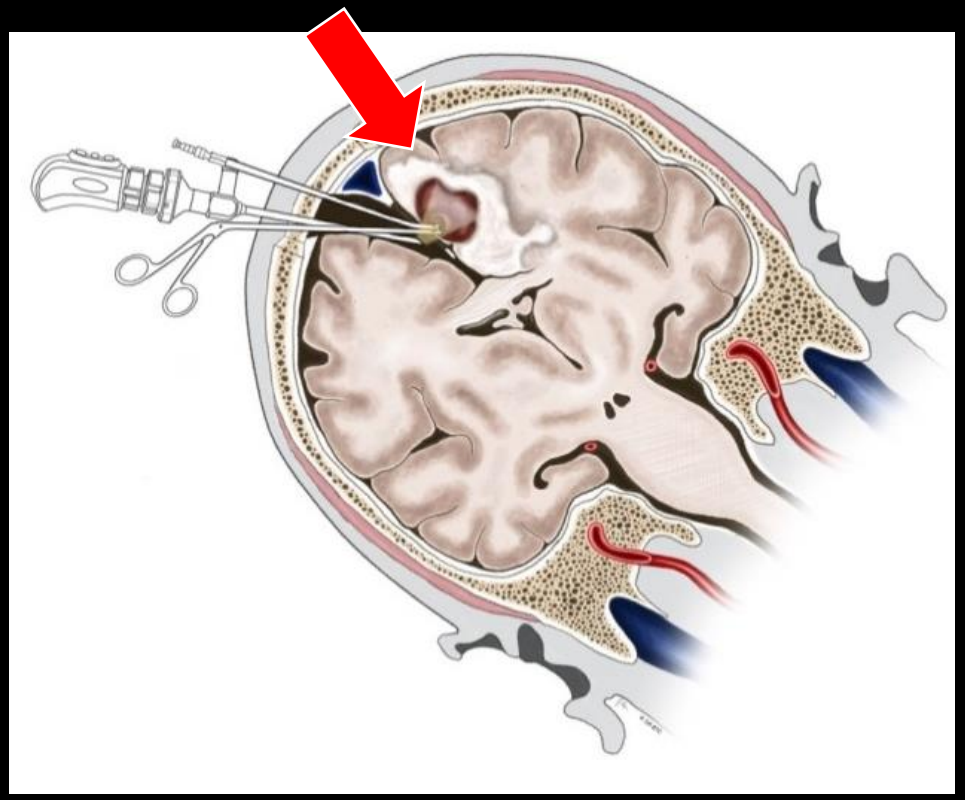

ENDOSCOPIC GRAVITY-ASSISTED TRANSFALCINE APPROACH
Barkhoudarian et al 2016

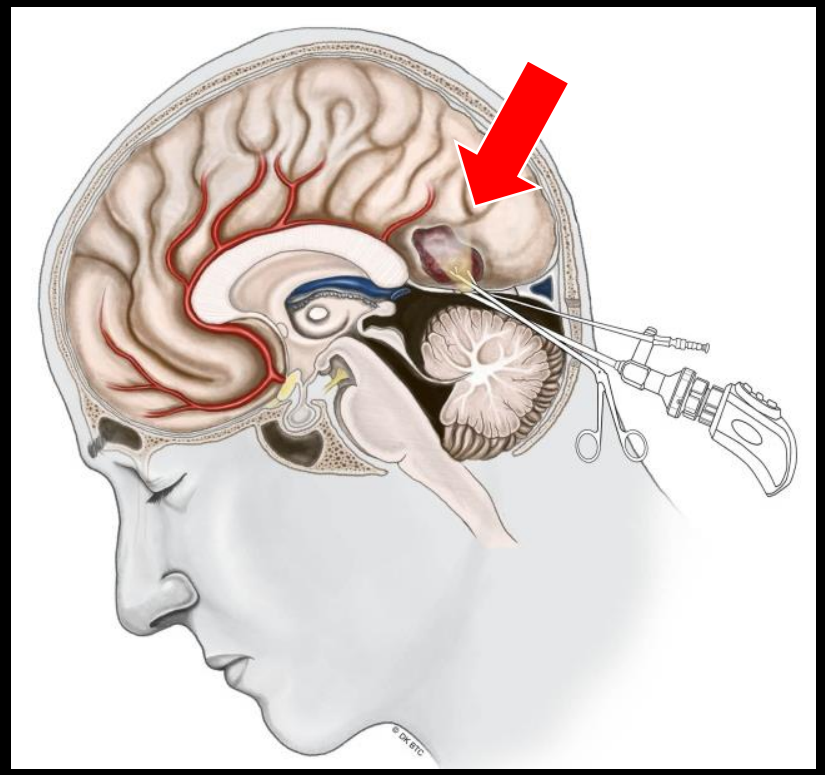

ENDOSCOPIC GRAVITY-ASSISTED TRANSTENTORIAL APPROACH
Villanueva et al 2015

Transfalcine Approach for Contralateral Tumors

- Goel A. Transfalcine approach to a contralateral hemispheric tumour. Acta Neurochir (Wien). 1995;135(3-4):210-2

- Ferroli P, Russo A, Albanese E, Tringali G, Broggi G. Gravity-aided trans-falcine removal of a contralateral subcortical ependymoma. Acta Neurochir (Wien). 2007 Nov;149:1147-50

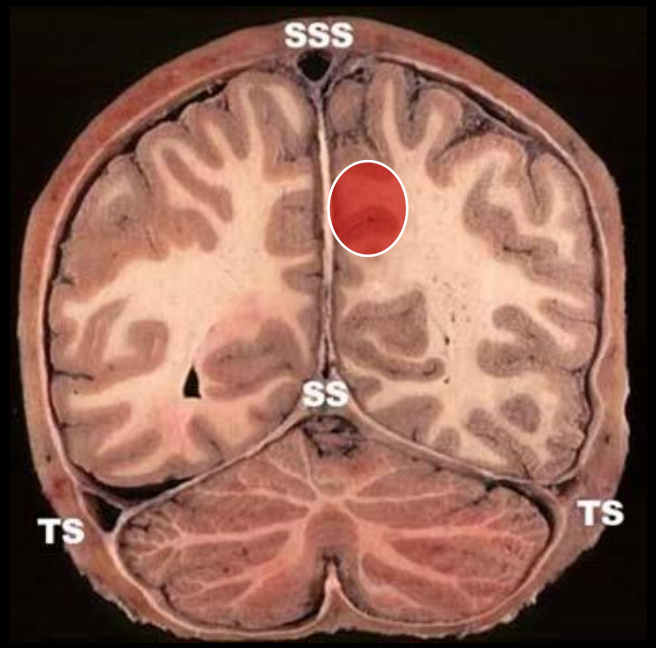

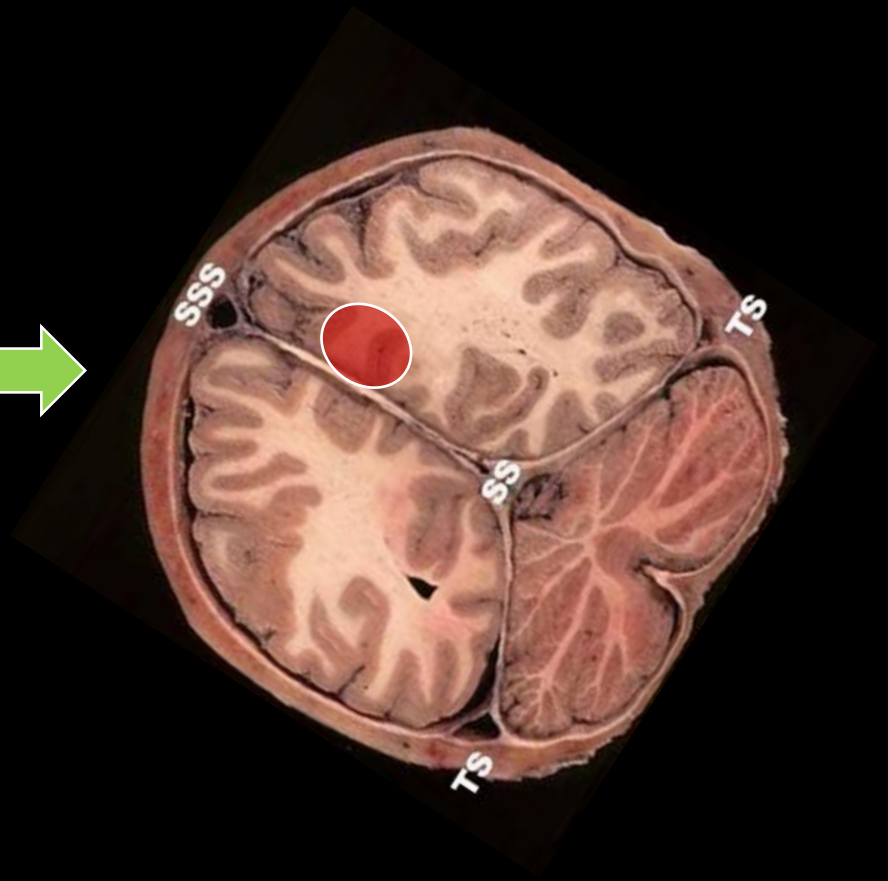

Transfalcine Approach: Positioning

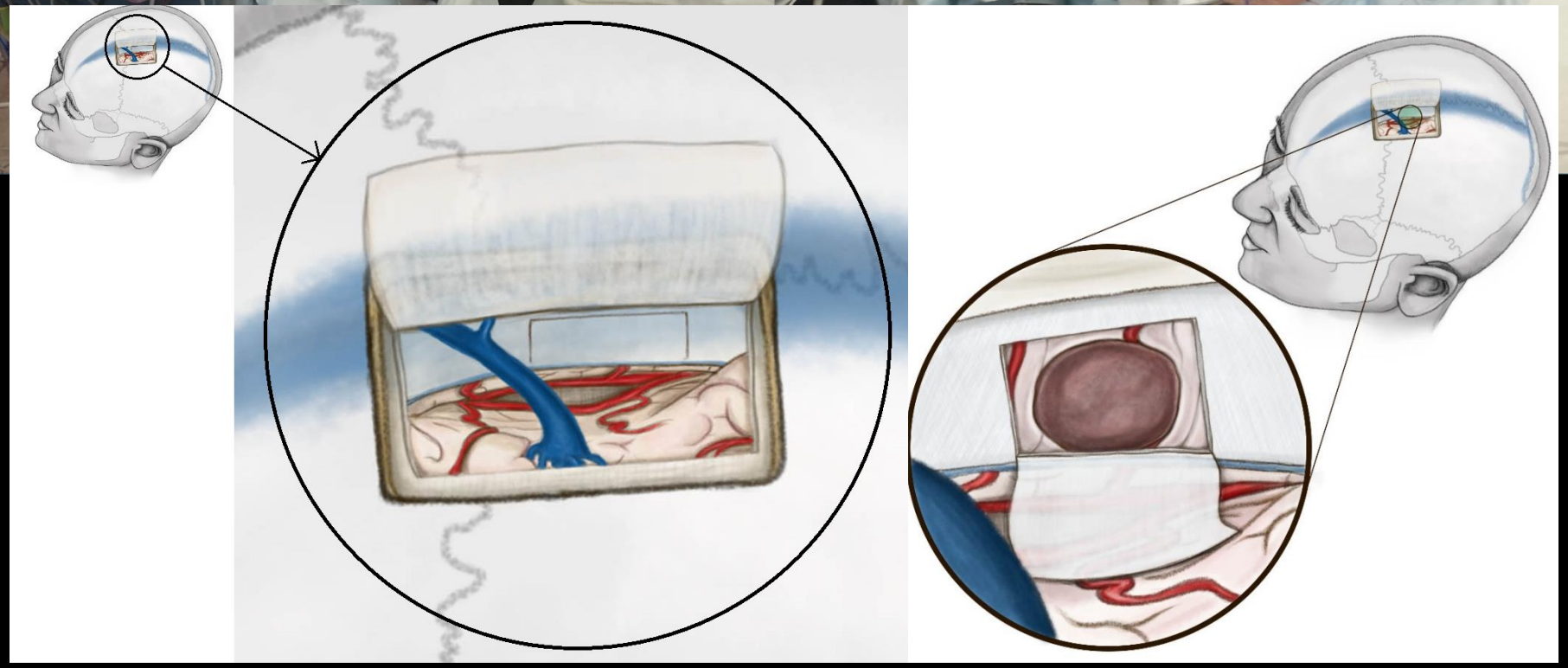

Metastatic Melanoma in 58 yr old Woman

Right-sided approach for left parafalcine tumor

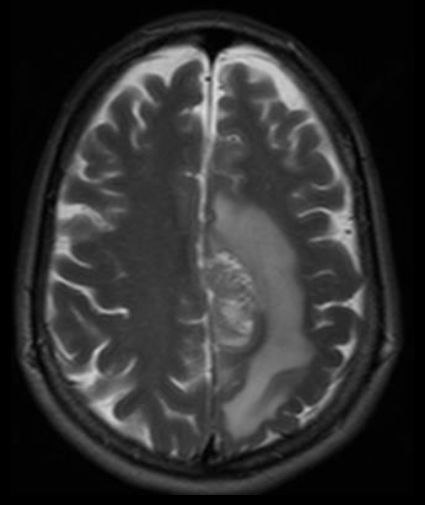

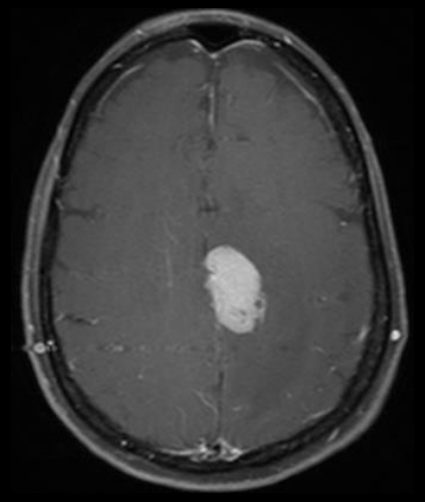

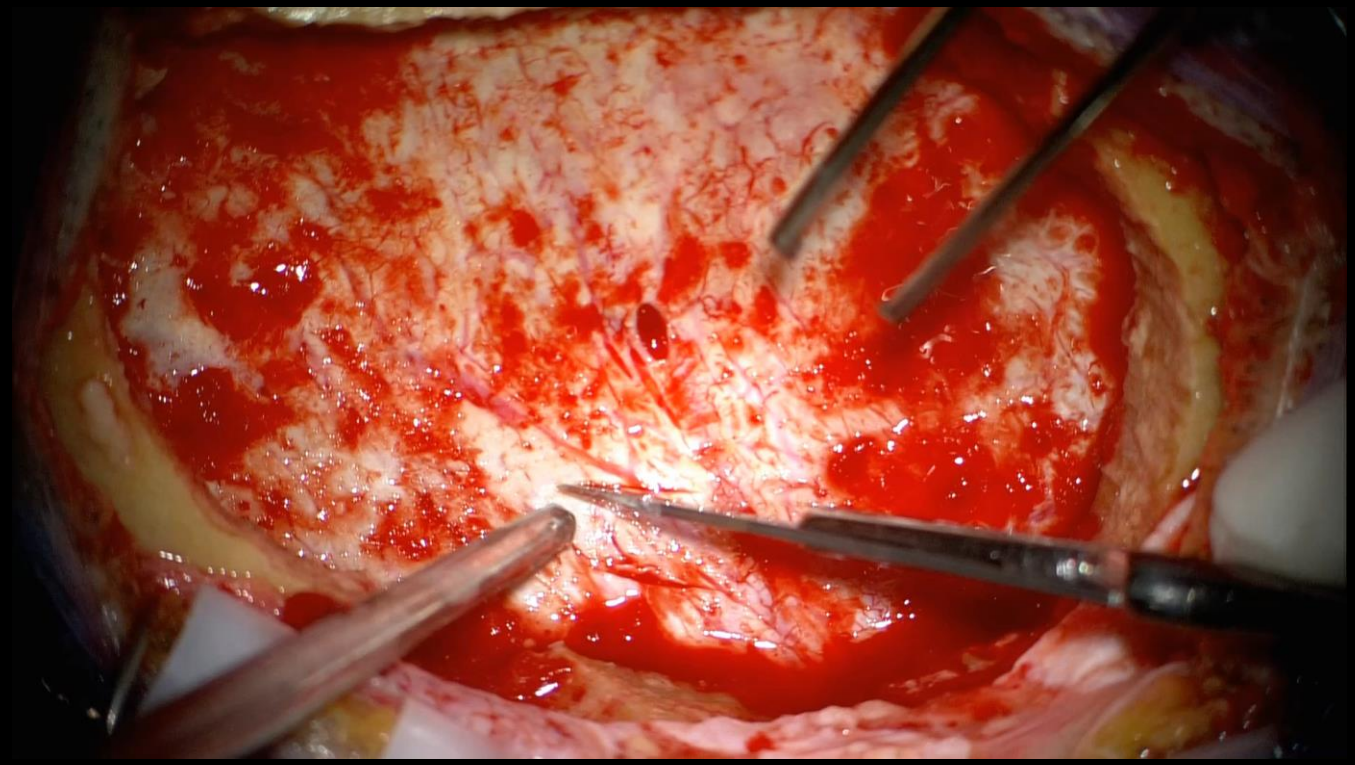

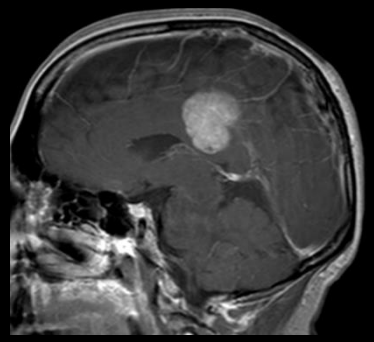

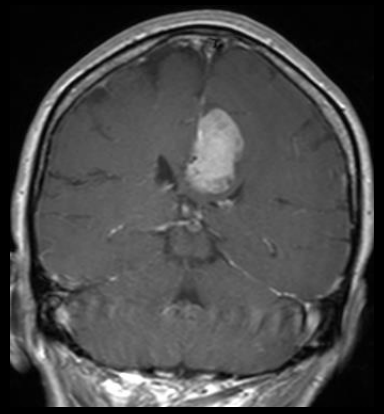

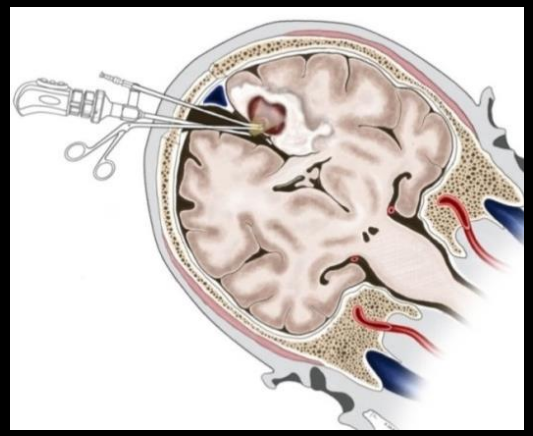

Pre-op

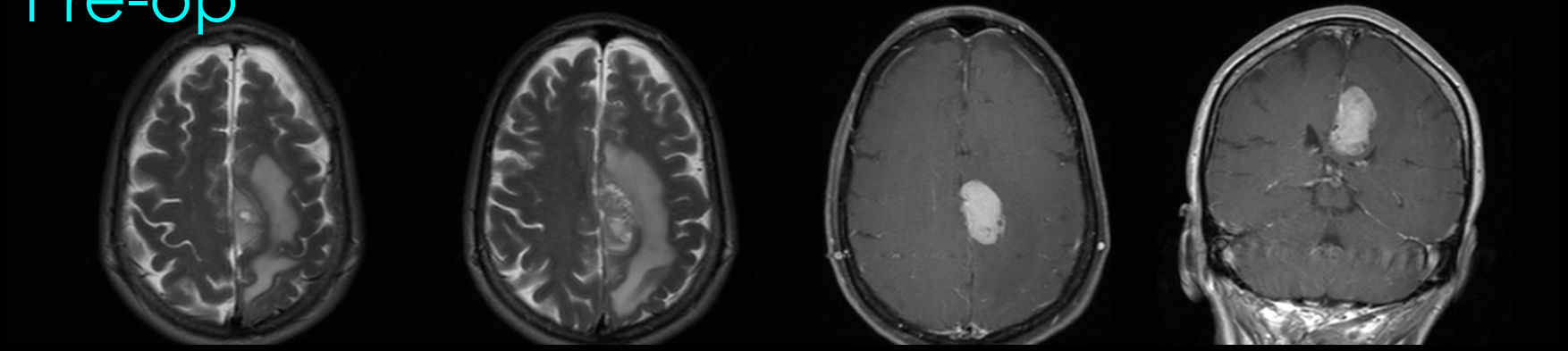

Post-op day 1

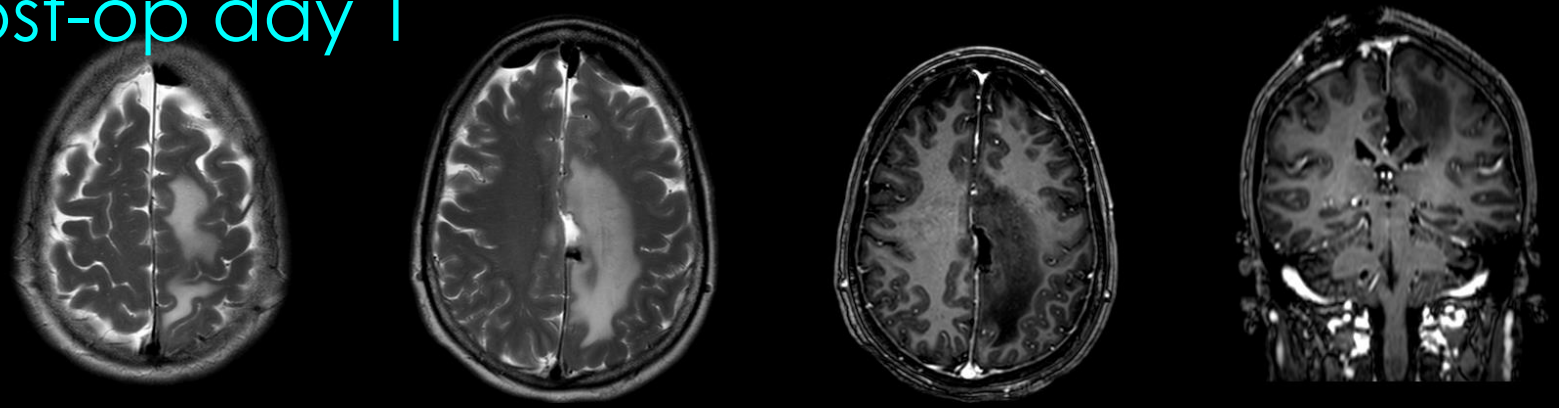

Post-op day 15 – *rapid edema resolution*

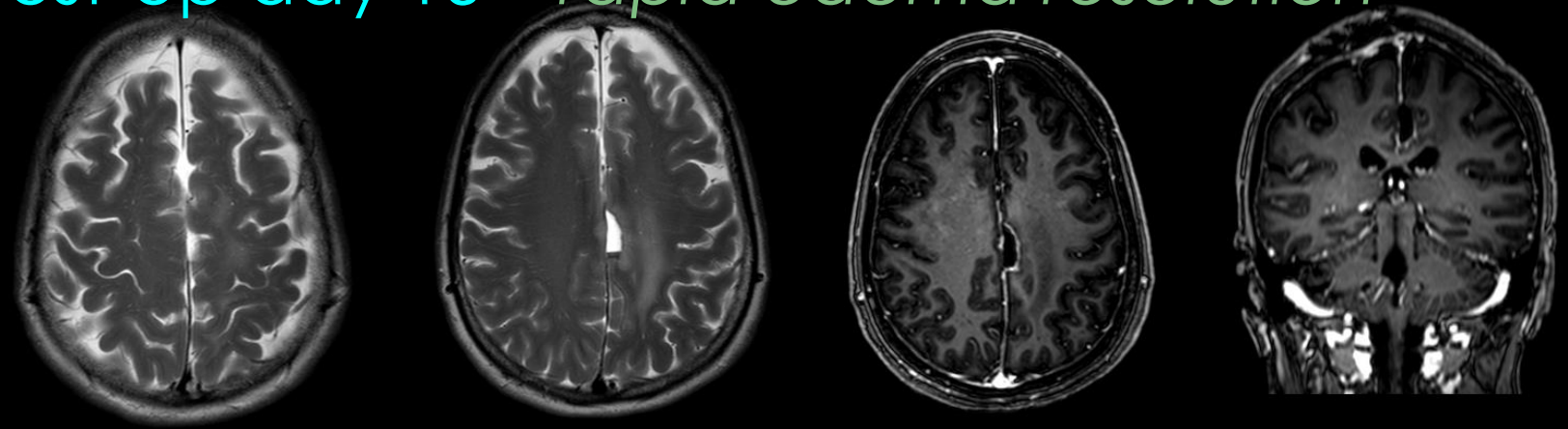

Gravity-Assisted Trans-Tentorial Endoscopic Approach

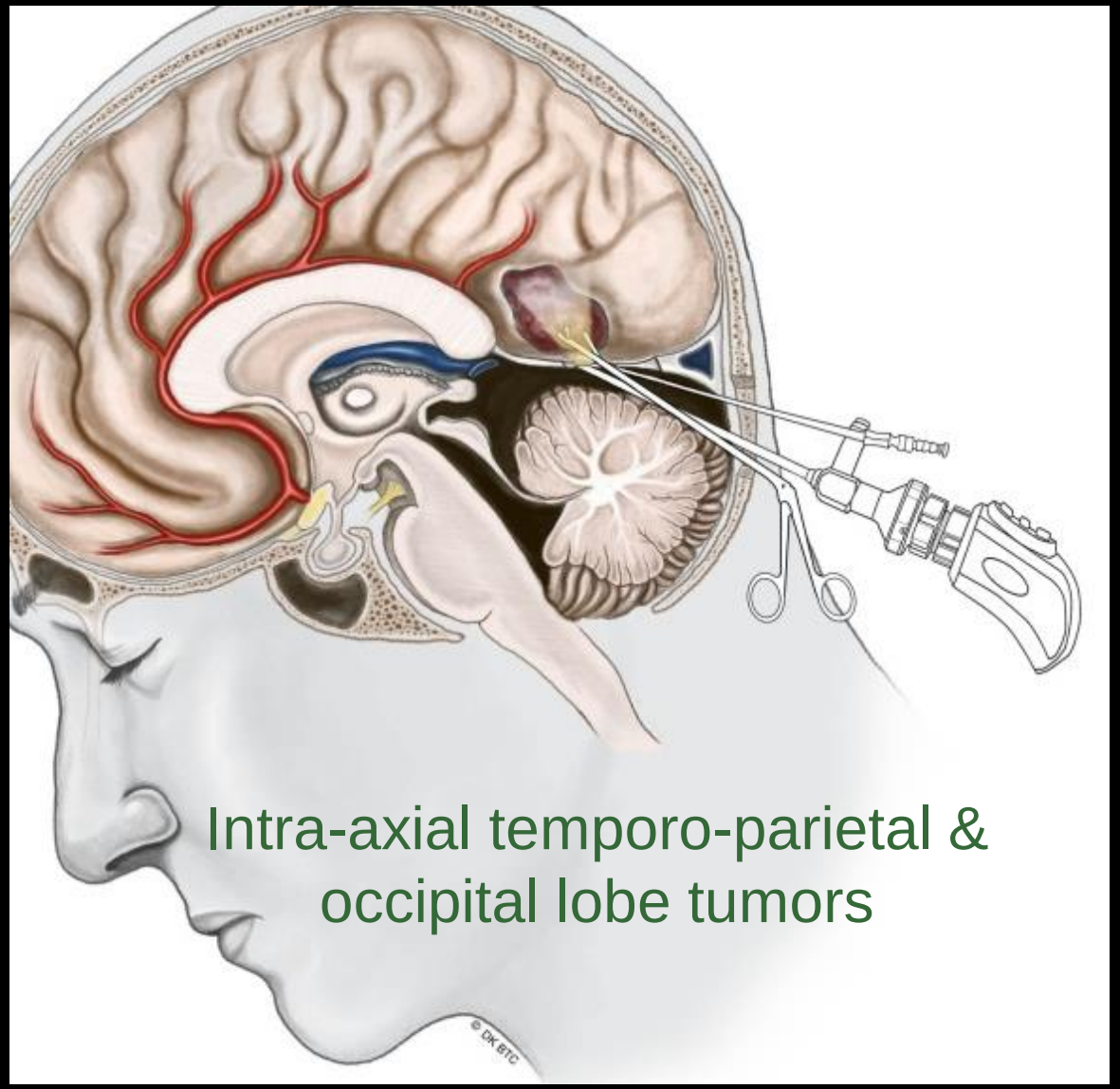

Metastatic Melanoma

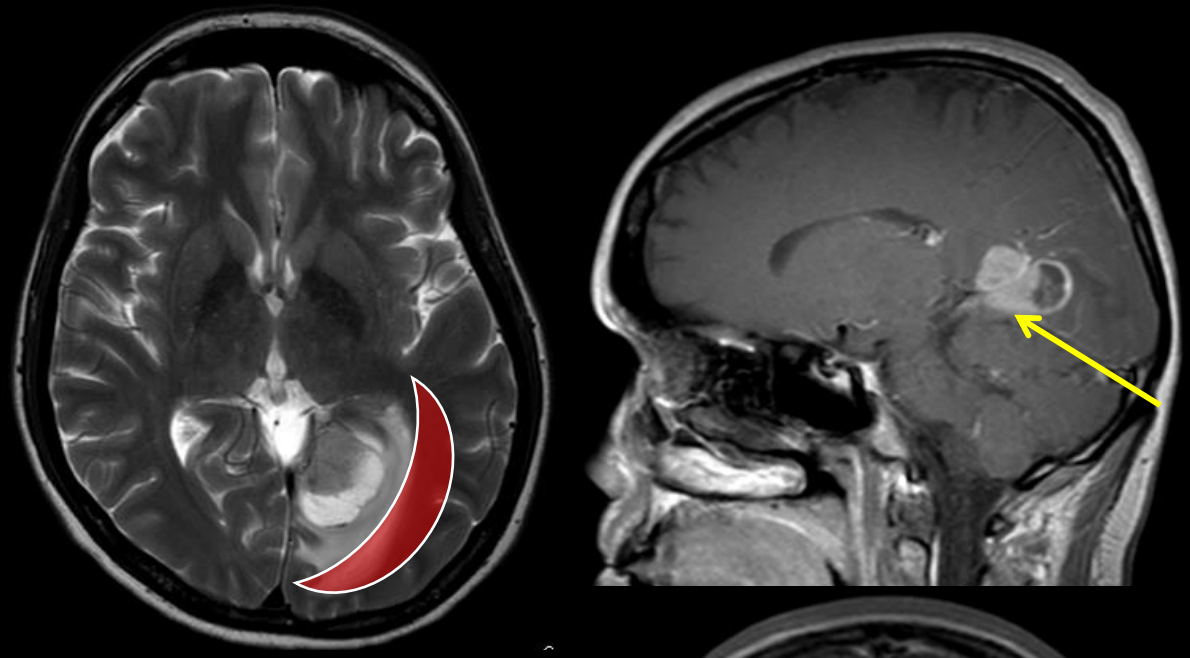

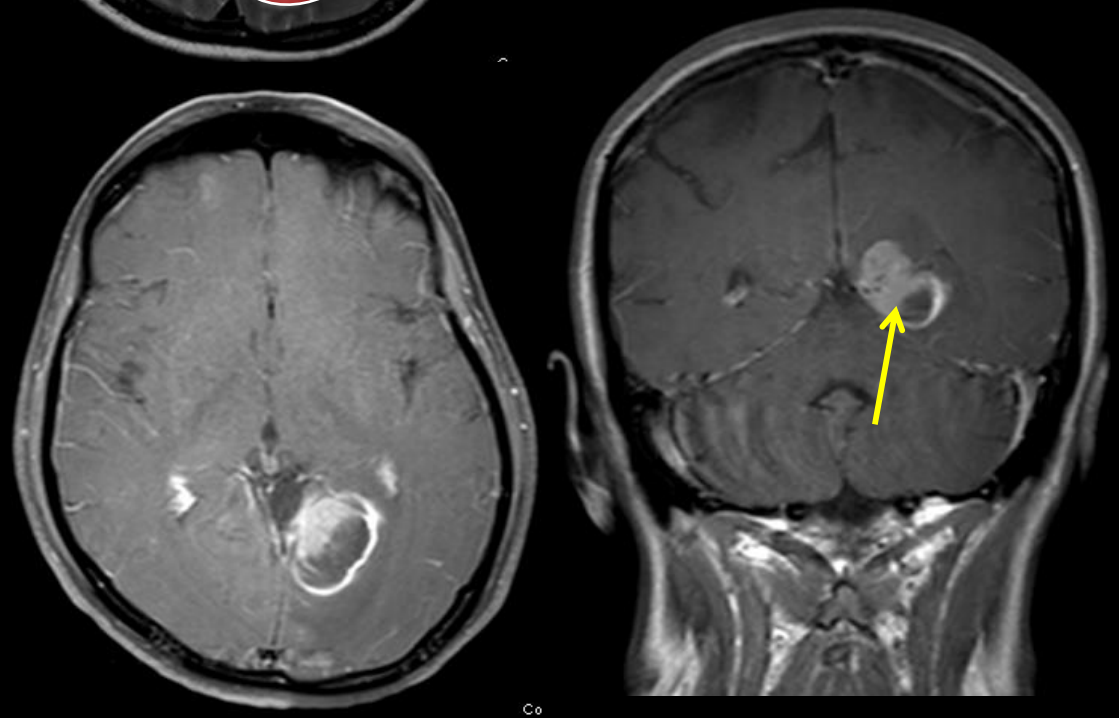

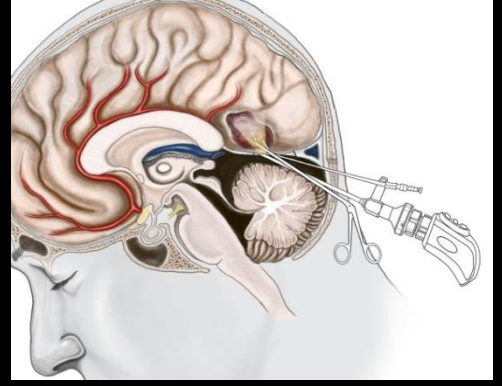

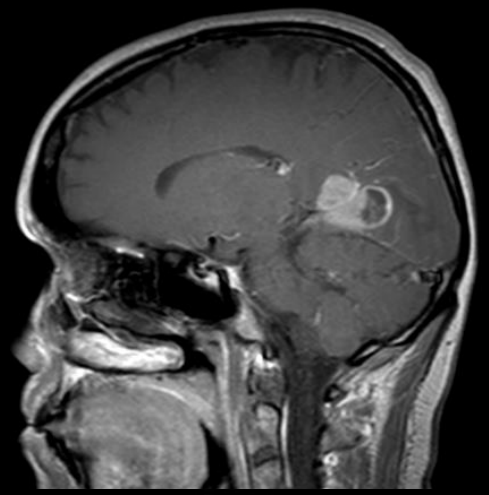

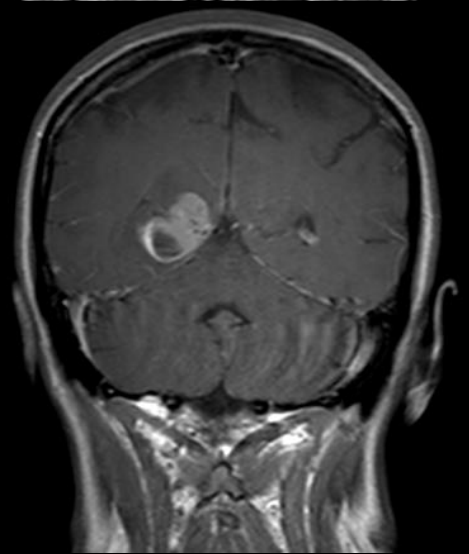

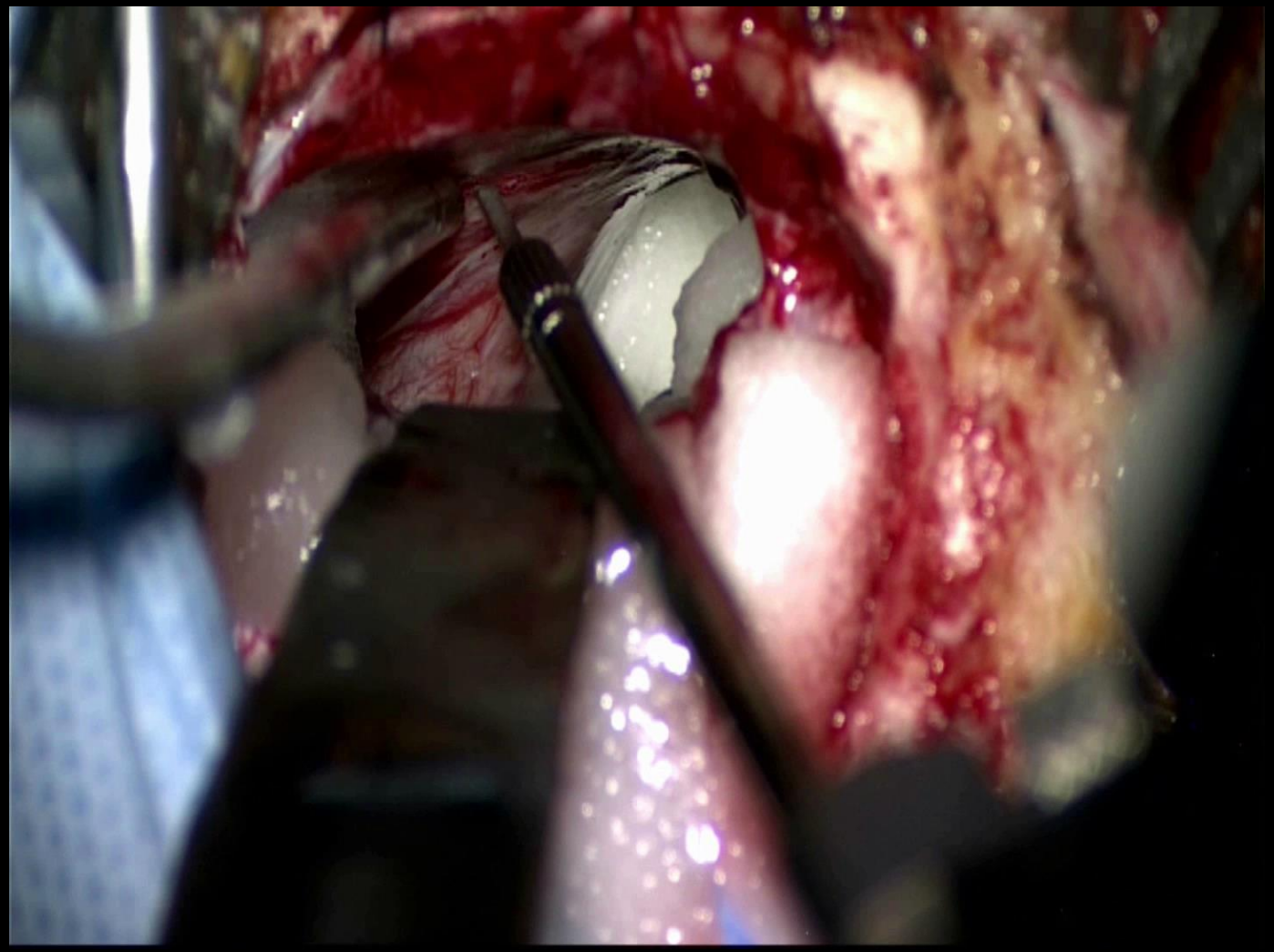

Post-op Day #1

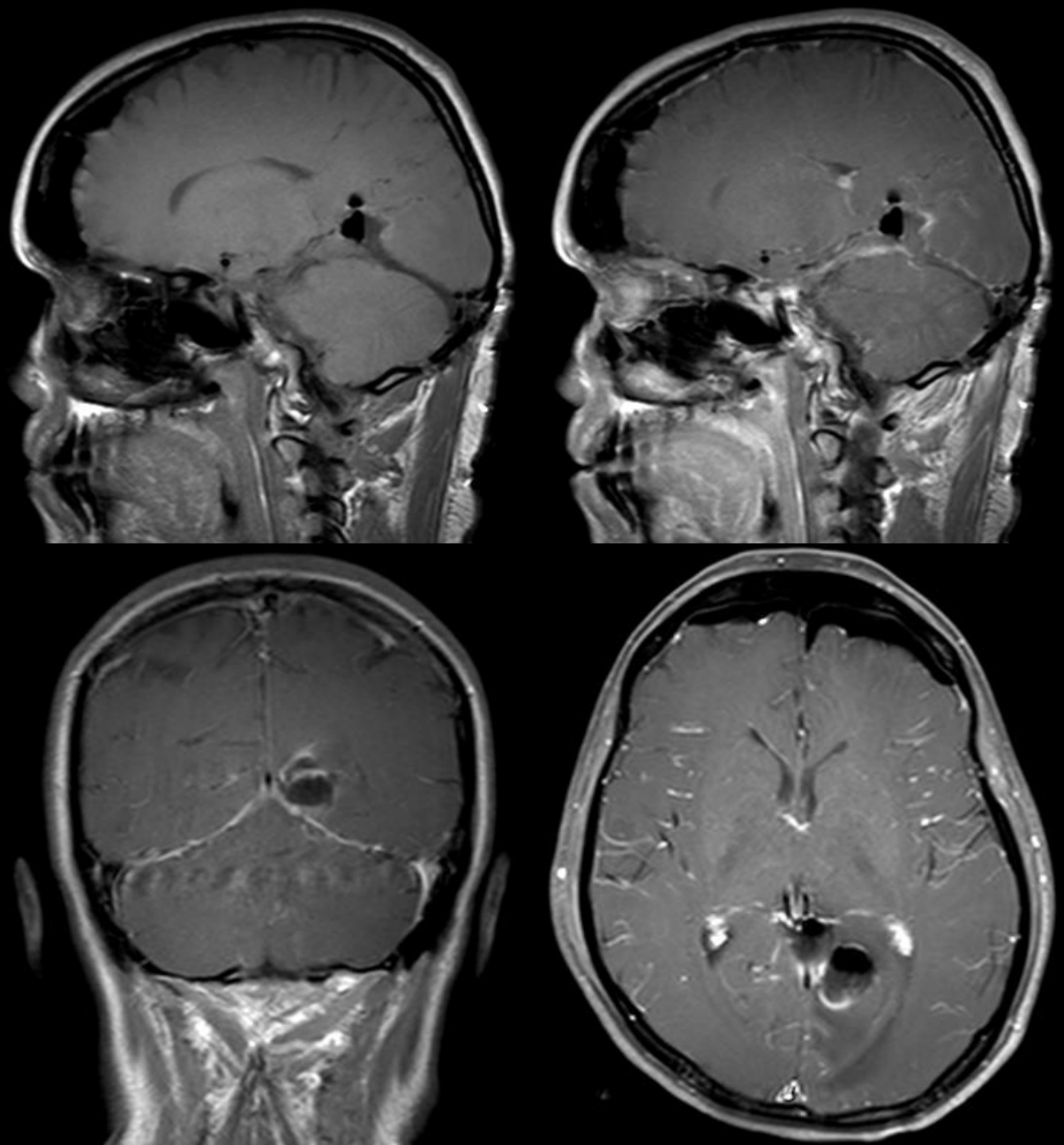

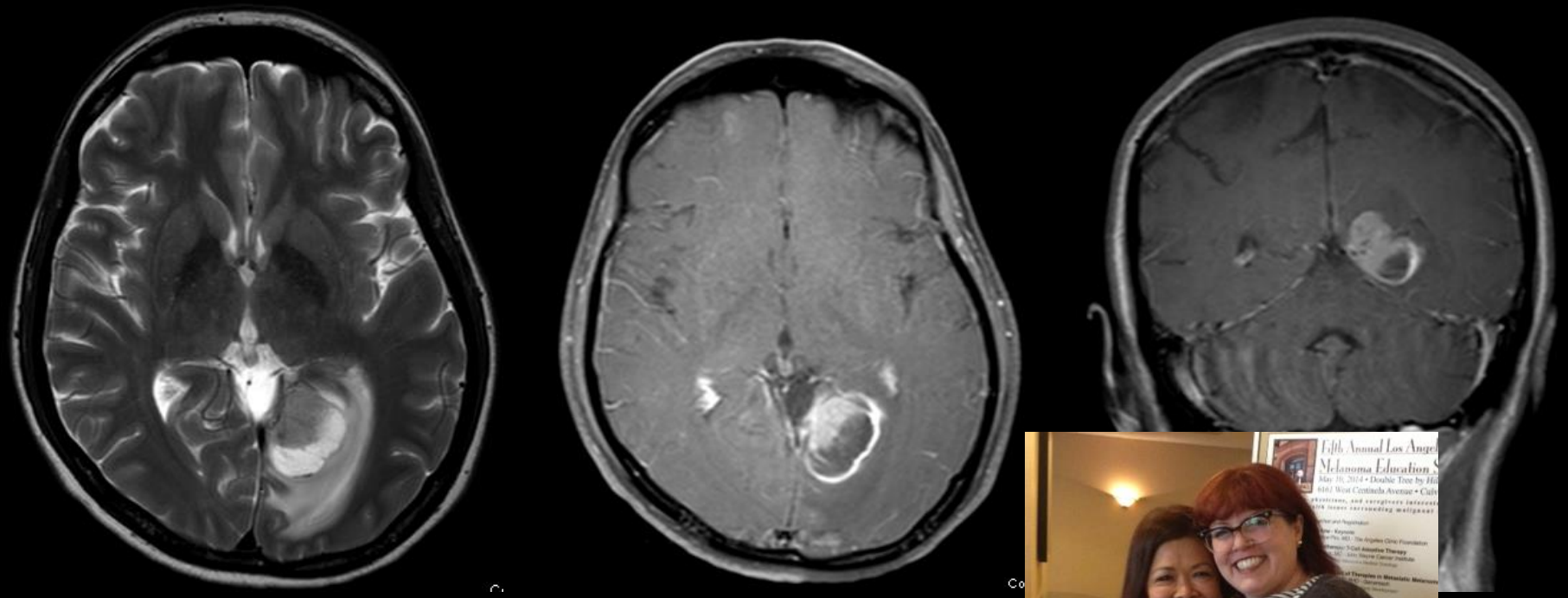

3 Months Post-op & Post SRS

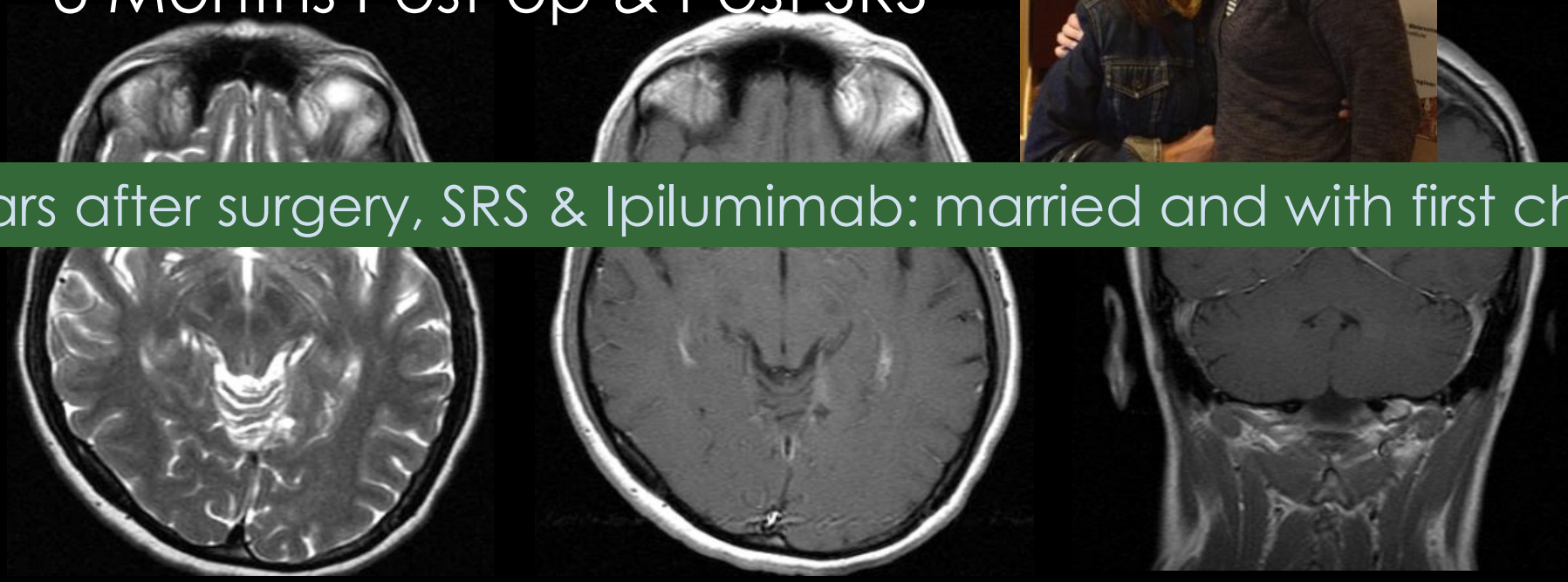

4 years after surgery, SRS & Ipilumimab: married and with first child

Brain Port Approach

64 yr old woman with deep GBM

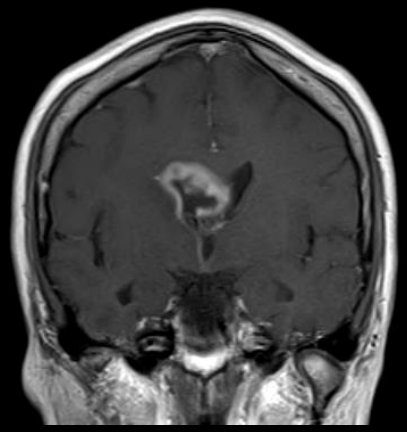

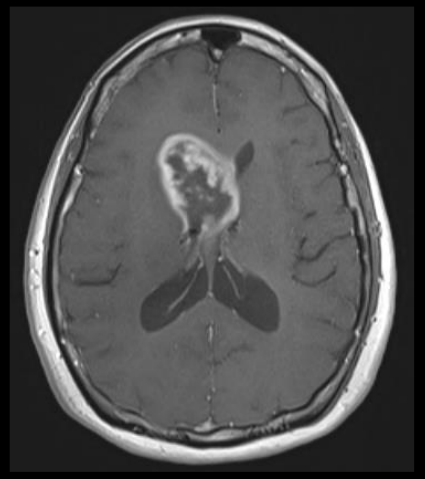

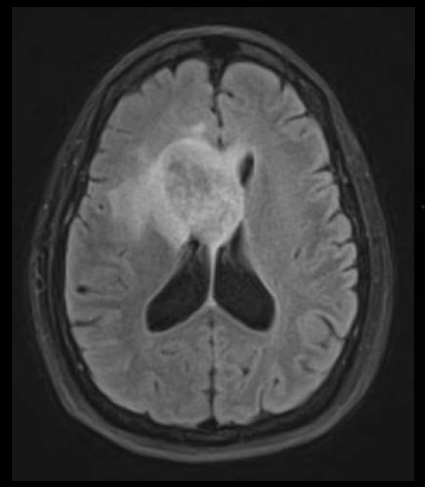

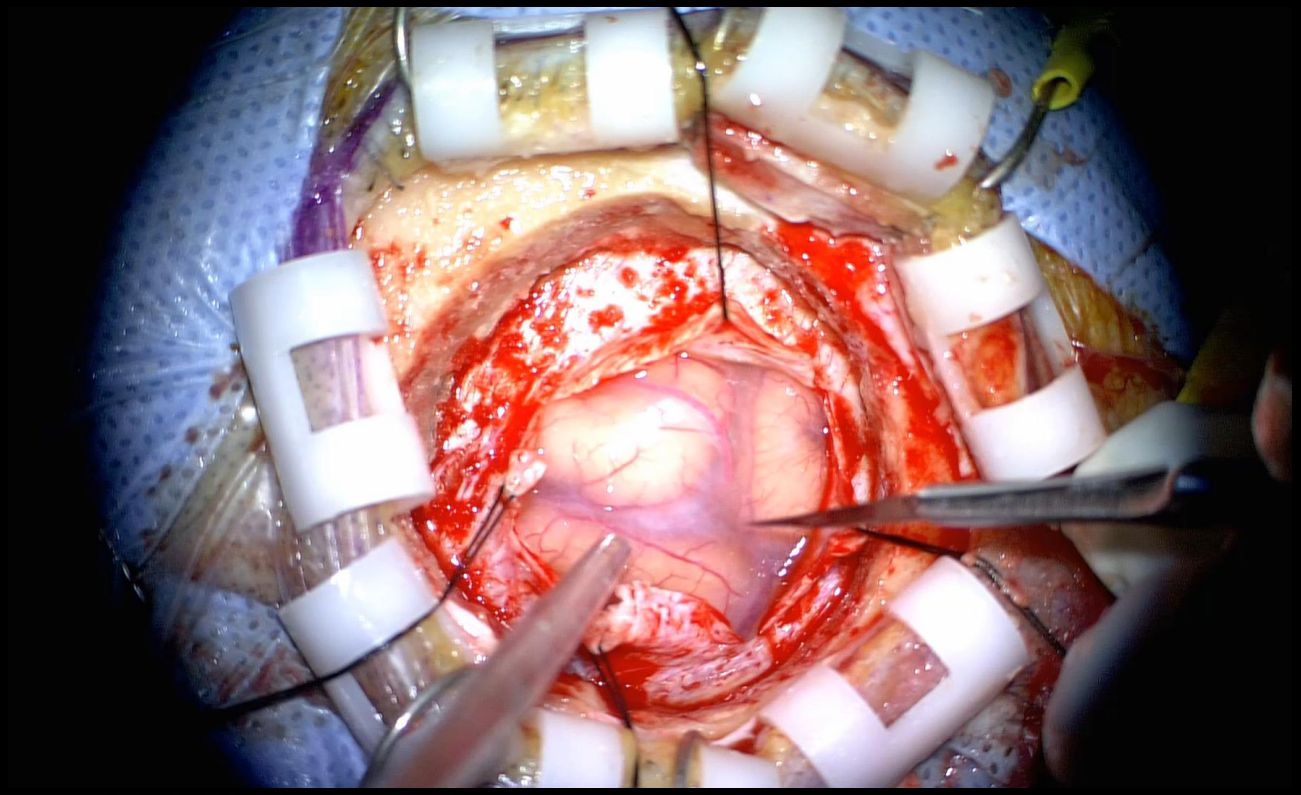

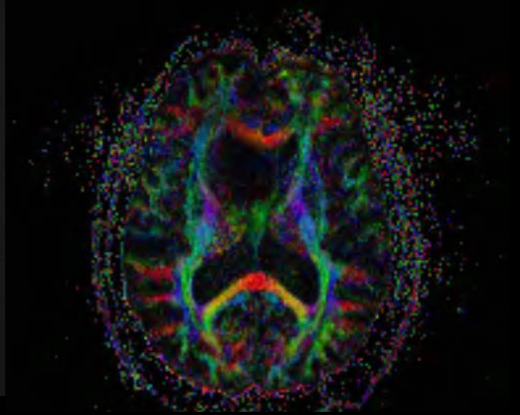

Brain Port Approach

64 yr old woman with deep GBM

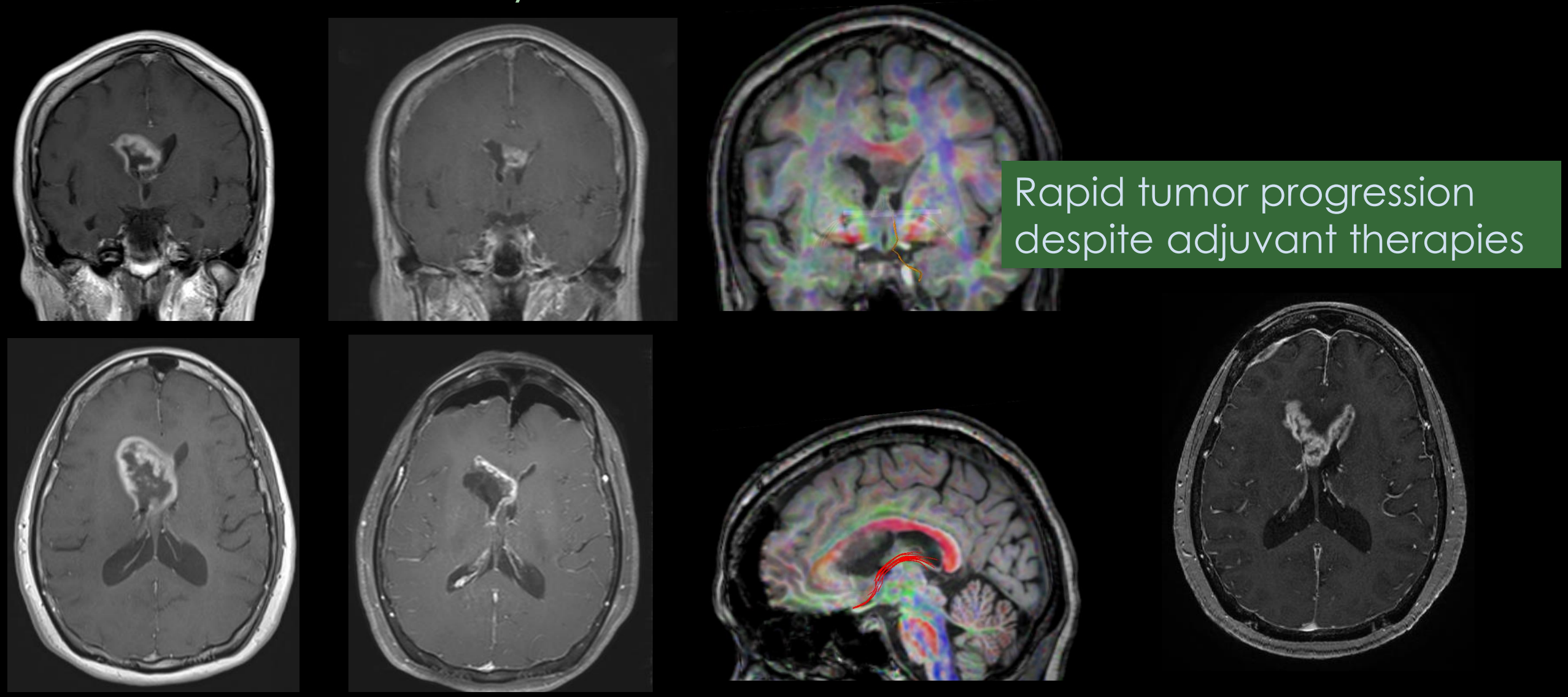

Rapid tumor progression despite adjuvant therapies

Conclusions

- Keyhole surgery is a *concept* not a size; surgical approaches need to be adaptable to the full spectrum of brain tumor pathology
- Advanced technologies are helping promote greater tumor removal while minimizing collateral damage
- When combined with targeted radiosurgery, medical therapies and immunotherapy, we are entering a new era in brain tumor management
- Collaborative team approach essential to optimize patient outcomes

PACIFIC Neuroscience SYMPOSIUM

September 22-23, 2017